

Multimodal Treatment of CONGENITAL NYSTAGMUS A Case Study

- Marcelline A. Ciuffreda, B.A.¹
- Andrea L. McCann, B.Sc.²
- Carl F. Gruning, O.D.³
- Kenneth J. Ciuffreda, O.D., Ph.D.⁴

1. Optometry Student, New England College of Optometry, 424 Beacon Street, Boston, MA 02115
2. Optometry Student, Illinois College of Optometry, 3241 South Michigan Avenue, Chicago, IL 60616
3. Eye Care Associates of Fairfield, P.C., 2600 Post Road, Southport, CT 06890
4. SUNY/State College of Optometry, Department of Vision Sciences, 33 West 42nd Street, New York, NY 10036

Abstract

Congenital nystagmus (CN) is characterized by abnormal, involuntary, rhythmic ocular oscillations that occur independently of and superimposed upon one's normal eye movements. There are many theories related to the pathogenesis and treatment of congenital nystagmus. However, few studies have reported the use of multiple treatment modalities in these patients to reduce their nystagmus and optimize visual performance. This case study outlines the general examination procedures and optometric findings of a male teenager with congenital nystagmus involving such a multimodal treatment strategy. The treatment regimen included maximum refractive correction with compensatory prism and a program of conventional optometric vision therapy, as well as experimental use of soft contact lenses. Improvements included increased visual acuity, reduced nystagmus, markedly improved near point of convergence, increased stereoacuity, much greater control of the exotropia, and improved cosmesis. Objective eye movement recordings were taken at the end of therapy to illustrate the differen-

tial effects of the multimodal treatment methods on nystagmus reduction. The results demonstrate the efficacy of such a multi-faceted optometric approach in the clinical treatment of congenital nystagmus.

Key Words

congenital nystagmus (CN), contact lenses, eye movements, optometric vision therapy, prisms, Visagraph

INTRODUCTION

Nystragmus refers to abnormal movement of the eyes that is comprised of rhythmic oscillations occurring independently of and superimposed upon one's normal eye movements.^{1,2} It can be categorized as either congenital, which is present at or within the first few months of birth, or acquired, which has a pathological genesis and is essentially age independent. Further classification of the nystagmus eye movements themselves can be made based on whether the motion is of a "jerk" or "pendular" pattern. In the "jerk" form, the eyes cycle through a slow phase, in which they deviate relatively slowly in one direction, and a fast phase, in which they rapidly return via a corrective saccade towards the starting point. In contrast, in the "pendular" form, relatively symmetrical and slow eye movements occur in both directions.

CONGENITAL NYSTAGMUS

Congenital nystagmus (CN) is most commonly found in the horizontal direction, and rarely in the vertical or torsional directions.¹ It is usually conjugate, and it

is accentuated by the attempt or effort to fixate, increased attention to a task, or anxiety. It may be dampened by convergence and lid closure.^{1,2} In approximately 30% of the cases, nystagmus occurs in association with strabismus.¹ Congenital forms are asymptomatic, because the brain adapts to the constant motion and essentially negates the increased retinal-image motion via special visual information processing.³ Periods of foveation (approximately 100 msec) within the cyclical motion have also been cited for the less than expected loss in visual acuity and relative lack of other adverse visual effects.⁴⁻⁶

There are several differential diagnoses that must be initially considered in congenital nystagmus. These include albinism (differentiated by transillumination defects and foveal hypoplasia), Leber's congenital amaurosis (differentiated by an abnormal electroretinogram), central nervous system disease, spasmus nutans, optic nerve or chiasmal glioma, optic nerve hypoplasia, congenital cataracts, and aniridia.⁷

The pathogenesis of congenital, idiopathic nystagmus is largely unknown. Theories have been postulated concerning possible etiological mechanisms. For example, Broomhead suggested an abnormality in the relationship between oculomotor burst cell activity and motor error,⁸ or presence of a "mis-wiring" of an oculomotor-related component in the visual pathway.¹

A genetic component has been identified, with potential modes of inheritance as either X-linked, autosomal dominant, or autosomal recessive.⁹ X-linked is the most common presentation, while

autosomal dominant is the rarest. Two candidate regions on the arms of the X chromosome have been linked to CN, as well as another region on chromosome 6.⁹ Classification of the lineage is often difficult due to the sub-clinical nature of mild forms of congenital nystagmus that may prevent family members from being identified correctly. This could account for the appearance of decreased penetrance.

Conventional treatment methods for nystagmus have included full refractive correction, use of prisms either to induce convergence effort (BO prisms) or to reduce the head turn (yoked prisms) or both (composite prisms),^{2, 10-11} along with a variety of extraocular muscle surgical procedures.¹² If a large strabismus is present, compensatory prisms may also be incorporated in the optical correction. In addition, other options have been demonstrated to be beneficial, such as orthoptics/optometric vision therapy¹³⁻¹⁹ and contact lenses.^{2, 10, 20-25} Current research has also shown acupuncture,²⁶ biofeedback,⁴⁻⁶ and head/neck stimulation to provide nystagmus reduction,^{27, 28} although these are not conventional modes of treatment. Lastly, some drugs have been found to have a temporary dampening effect, including gabapentin, baclofen, and valproate.¹

CASE HISTORY AND INITIAL CASE FINDINGS

Patient DH, a pleasant, mild-mannered 16-year-old white male, presented to our office in July, 2003. After failing the vision screening at the Department of Motor Vehicles, DH and his mother chose to explore the option of optometric vision therapy to dampen and control DH's nystagmus with the hope of improving his visual acuity to a level sufficient to obtain a driver's permit. Most interestingly, DH is active in competitive go-cart racing.

Ocular history revealed that DH underwent strabismic surgery on his right eye without complication at age 7 years. Records obtained from the surgeon confirmed a right medial rectus resection and a right lateral rectus recession to compensate for DH's constant 35PD right exotropia. The surgical procedure temporarily reduced the exotropia to a small exophoria.

One month prior to being examined in our office, DH was examined by another ophthalmologist. Here DH first acknowledged a long-term problem with constant

	Pre-Training (with Fresnel Prism)	Post-Training (with Fresnel Prism)	Post-Training (without Fresnel Prism)	Post-Training (Trial Frame Rx with Prism)
VA OD	20/70 ⁻²	20/50 ⁻¹	20/50 ⁻¹	20/40 ⁻²
OS	20/60 ⁻²	20/50 ⁺²	20/40 ⁺¹	20/40 ⁺¹
OU		20/50	20/40	20/40 ⁻¹
Distance CT sc	35-40PD CAXT	8-10 PD XP	-----	-----
Distance CT cc	30-35PD CAXT	approx. ortho; w/ prolonged testing, 8-10 XP	8-10 PD XP	approx. ortho; w/ prolonged testing, 8-10 XP
Near CT sc	2-3PD RHypo/20PD CAXT'	10-12 PD XP'	-----	-----
Near CT cc	20PD XP'	6-8 PD XP'	8-10 PD XP'	6-8 PD XP'
CNP cc	30-36 inches/48 inches (penlight target)	5 inches/7 inches (penlight target) 1 inch/3 inches (accommodative target)	5 inches/7 inches (penlight target) 2 inches/4 inches (accommodative target)	5 inches/7 inches (penlight target) 1 inch/3 inches (accommodative target)
Worth 4 Dot	Constant Diplopia	Fusion ≤ 3 feet Diplopia >3feet	Fusion ≤ 3 feet Diplopia > 3 feet	Fusion ≤ 3 feet Diplopia > 3 feet
WIRT	Animals: 200 arc sec Circles: none	Animals: 200 arc sec Circles: 80 arc sec	Animals: 100 arc sec Circles: 60 arc sec	Animals: 100 arc sec Circles: 80 arc sec
Randot	-----	Animals: 400 arc sec Circles: 200 arc sec	Animals: 200 arc sec Circles: 100 arc sec	Animals: 200 arc sec Circles: 70 arc sec

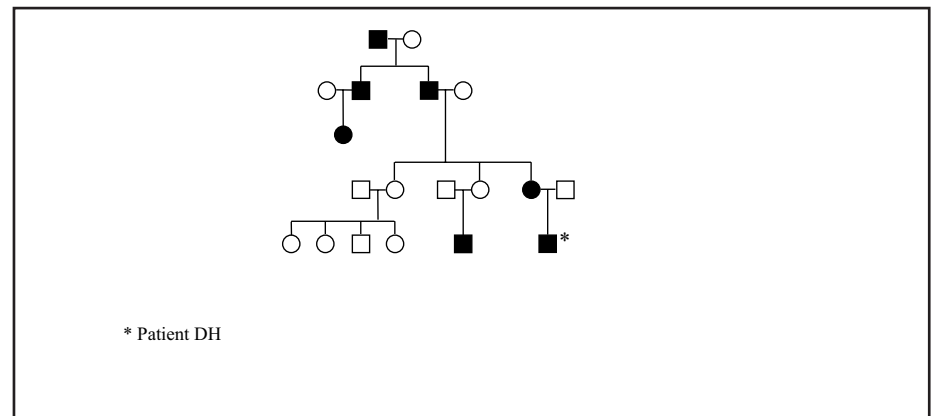


Figure 1: Pedigree of Inheritance Pattern of Nystagmus with Exotropia of Patient DH and His Family. Solid symbols = affected family members.

diplopia at near. The diplopia frequency was decreased with the addition of Fresnel prisms to his spectacle prescription (OD: +1.00D/-6.00Dx010, 5PD BI; OS: +1.00D/-4.00Dx155, 5PD BI). His ocular health was unremarkable OD/OS. Posterior pole evaluation was within normal limits with respect to the optic nerves, and the cup/disc ratio was 0.1 OD/OS. Macular regions were clear with foveal reflex present OD/OS.

At our initial evaluation of DH, his mother reported a normal pregnancy and birth without any pre- or post-natal com-

plications. All major developmental milestones for talking, walking, and gross/fine motor skills were age appropriate. A detailed family history revealed a strong inheritance pattern of congenital nystagmus (autosomal dominant with incomplete penetrance) accompanied by exotropia and high bilateral astigmatism (see Figure 1). The patient's medical history was positive for attention deficit hyperactivity disorder (ADHD) over the past four years, for which DH is currently taking 20mg of Medadate daily. DH had originally been taking 30mg daily; however,

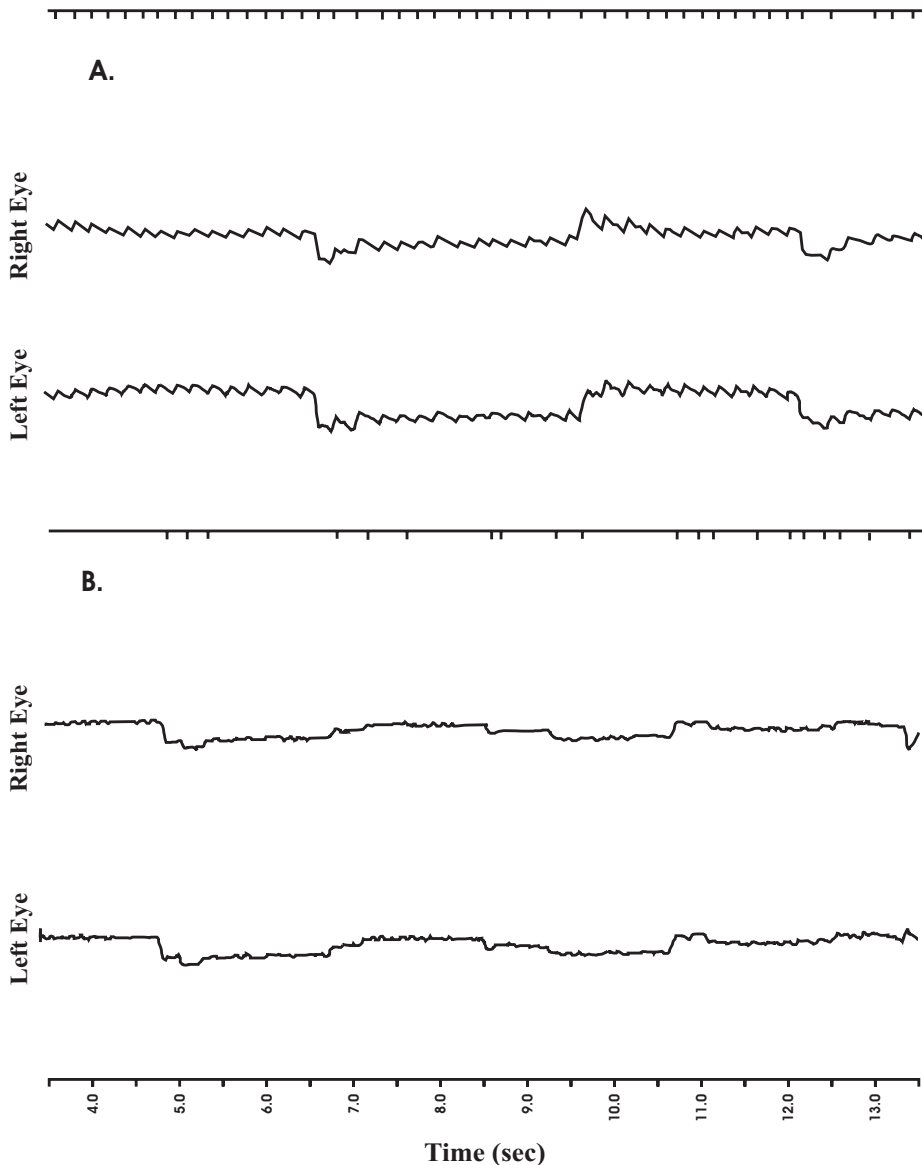


Figure 2. Horizontal eye position as a function of time. Binocular viewing. Patient is changing fixation every few seconds between 10 degrees left, 10 degrees right, and center. Up=rightward and down=leftward. Small tick marks denote jerks of nystagmus. A = Post-therapy without any form of optical correction. B = Post-therapy with spectacle lens correction, prisms, and soft contact lenses.

with this dosage, both DH and his mother felt that the nystagmus had significantly worsened. There is no current research definitively confirming this side effect of Medadate.²⁹

DH's entering (pre-training) corrected distance Snellen visual acuity (single line) was 20/70⁻² OD and 20/60⁻² OS (see Table 1). There was no improvement with pin-hole. Distance cover testing without correction revealed a 35-40 PD constant alternating exotropia (CAXT) that was reduced only to 30-35PD with correction. Near cover testing without correction revealed a 20PD CAXT with a 2-3PD right hypertropic component, which was reduced to a 10PD exophoria with his

spectacles. Accurate measurement of the phoria was confounded by presence of nystagmus and its inherent variability. Nearpoint of convergence with correction was significantly reduced, breaking at 30-36 inches (with either eye deviating outward and reported diplopia) with a fusional recovery of 48 inches. Extraocular motility testing revealed a V-pattern exotropia, and Worth-4-Dot demonstrated constant diplopia from 3 to 15 feet. Titmus Wirt testing revealed 200 arc sec stereoacuity. Color vision testing with pseudoisochromatic plates was normal in both eyes. Accommodative amplitudes and facility were within expected limits. Pupils were equally round and re-

active to light with no afferent pupillary defect noted in either eye. Confrontation fields were full to finger counting when tested in each eye. Ocular health examination of the anterior segment was normal. Iris transillumination was negative for albinism. We accepted the recent ophthalmological examination's normal dilated fundus findings.

TREATMENT RATIONALE

There are a number of potential treatment modalities to aid in the reduction of nystagmus and its associated symptoms, as described earlier. Each treatment has its own advantages. However, the present case study emphasizes a multimodal therapeutic approach producing the most benefit to the patient. This included refractive correction, prismatic correction, optometric vision therapy, and experimental testing with soft contact lenses.

Firstly, obtaining the most precise refractive correction was of the utmost importance, since the increased visual acuity may allow for improved fixation. This in turn can result in reduced nystagmus due to increased foveational stability. Secondly, the use of prism (initially 5PD and later 3PD BI for each eye) in the form of either ground-in or Fresnel lenses was used to reduce the large heterophoria/tropia. Thirdly, a very effective mode of nystagmus treatment is optometric vision therapy.^{2,11,13-19,30} A number of vision therapy procedures can produce a decrease in the nystagmus with a concurrent increase in visual acuity. The associated binocular dysfunctions, such as impaired overall fusion, reduced stereopsis, and reduced convergence and accommodative functions, can also be addressed and improved through vision therapy. Lastly, the use of contact lenses was considered. It has been demonstrated that the felt sensation of the contact lenses on the eyes provides proprioceptive feedback to the patient concerning their eye movements. This allows for potential control and reduction of the nystagmus amplitude.^{2,10} This holds true for both gas permeable as well as soft contact lenses.

In the case of DH, after our initial examination, it was decided that his prior ophthalmological lens and Fresnel prism prescription would initially be used while conducting all vision therapy procedures. In addition to the nystagmus, DH also had several other vision problems, including

diplopia from the exotropia, a markedly receded nearpoint of convergence, and reduced stereoacuity.

DH began a program of optometric vision therapy to address the nystagmus, exotropia, and overall binocular vision dysfunction. His specific goal was to achieve sufficient visual acuity to obtain a driver's permit. He was provided two vision therapy sessions per week, each session of a one hour duration for a period of four months. There was also home-training four days a week, approximately 10 minutes a day, to provide reinforcement of the in-office vision therapy. This included such procedures as red/green luster awareness, Wolff wand pursuit tracking, and the Brock string.

TREATMENT

Vision therapy was divided into the general categories of ocular motility, accommodation, binocularity, and eye-hand/perceptual-motor.³⁰⁻³² The focus of the therapy was placed on improving ocular motility, fixation and alignment, as well as convergence ability and overall binocularity. There was less emphasis on accommodation, since initial testing found this area to be relatively normal. The techniques used are conventional vision therapy procedures for the various areas.³⁰⁻³² For example, the Brock String, vectograms and Keystone Stereogram cards AN 6 and 10 were used to enhance binocularity. Many of the techniques used the VTS (Visual Training System) Computer Programs.^a For example, the System's Visual Tracing and Visual Motor Integration programs were used with anaglyphs to enhance ocular motility, fixation, binocularity and eye-hand/perceptual motor functions. Standard monocular and binocular accommodative procedures were also used. Additionally, a number of out-of-instrument techniques were used to enhance diplopia awareness, peripheral awareness, eye-hand coordination and reaction time.

In addition, a procedure involving contrast sensitivity was used to reduce the nystagmus. DH viewed a contrast sensitivity function chart at the contrast and spatial frequency levels where he first was unable to perceive grating orientation. His task was to then attempt to reduce his nystagmus sufficiently through the previously learned internal control

**Table 2:
Nystagmus Frequency (Hz) as Measured Using the Visagraph Eye
Movement Recording System Post-Therapy Under a Variety of
Corrective Conditions During Fixation**

	No Spectacle or Prismatic Correction	Full Spectacle Correction with Fresnel Prisms	Full Spectacle Correction without Fresnel Prisms, and Soft Contact Lenses	Full Spectacle Correction with Fresnel Prisms, and Soft Contact Lenses
Center	5.0 Hz	4.7 Hz	3.1 Hz	1.5 Hz
Right 10	4.1 Hz	4.5 Hz	4.4 Hz	1.3 Hz
Left 10	4.3 Hz	4.6 Hz	3.9 Hz	2.5 Hz

mechanisms,¹⁰ in order to just detect the grating orientations correctly.

PROGRESS EVALUATIONS

Interim progress evaluations were performed throughout the four months of vision therapy. These revealed progressive decreases in nystagmus, markedly improved control of the strabismic deviation, improved visual acuity, diminished diplopia, and markedly increased convergence ability. These findings were also confirmed by parental and family observation, as well as patient testimonials.

At the end of the four months, post-therapy testing was conducted to determine carefully the extent of improvement, in particular visual acuity for the driver's permit approval. The major test results are listed in Table 1. The three post-training columns represent the various combinations of his spectacle and prismatic correction used in the evaluation. This was done to determine the optical combination that best reduced the nystagmus and maximized vision function. Therefore, the tests were performed firstly through his current prescription with the Fresnel lenses in place, secondly, through this prescription but with the Fresnel lenses removed, and finally with the prescription in a trial frame to include the prismatic component while eliminating the visual degradation produced by the press-on Fresnel prisms.

In addition, at the end of vision therapy, objective horizontal eye positions of both eyes were recorded during binocular viewing at a test distance of 57cm. This was done using the Visagraph reading eye movement system.^{b,33} It has a linearity of at least $\pm 10^\circ$, a resolution of 0.25° , and a bandwidth (i.e., frequency response) from dc to 50Hz. Various combinations of spectacle, prism, and contact lenses (-0.50DS) were assessed, while DH fix-

ated centrally along the midline, as well as 10° degrees to the left and right of center. The nystagmus frequency was quantified, and the nystagmus amplitude was qualitatively assessed, under each lens and fixation condition by manual assessment from the hard copy eye movement records using from one to three artifact-free 10-sec segments of the records.

RESULTS

At the end of the four months of training, considerable improvement was noted in most areas (See Table 1). Most importantly, his Snellen visual acuity (single letter and whole line) of 20/40OU was now sufficient to allow him to attain his primary goal of obtaining a driver's permit. Other significant improvements included: markedly decreased nystagmus frequency and amplitude, markedly improved near point of convergence, increased stereoacuity, and virtual elimination of the diplopia and exotropia under naturalistic conditions.

The efficacy of the multiple combinations of optical correction for nystagmus reduction is evident from the objective eye movement recordings. The reduction in both the nystagmus frequency and amplitude with full refractive and prismatic correction along with the proprioceptive feedback from the contact lenses as compared to without any form of optical correction is most striking (Figure 2 and Table 2). The soft contact lenses reduced the nystagmus frequency from approximately 5 Hz (i.e., five jerks or "beats" per second) with the correction and prism to, at times, 1 Hz or less per second. The effect of multiple corrective combinations is also revealed by the difference in reduction of nystagmus frequency when comparing the two versus three-component treatment (Figure 3 and Table 2). With the spectacle correction and prism (Figure

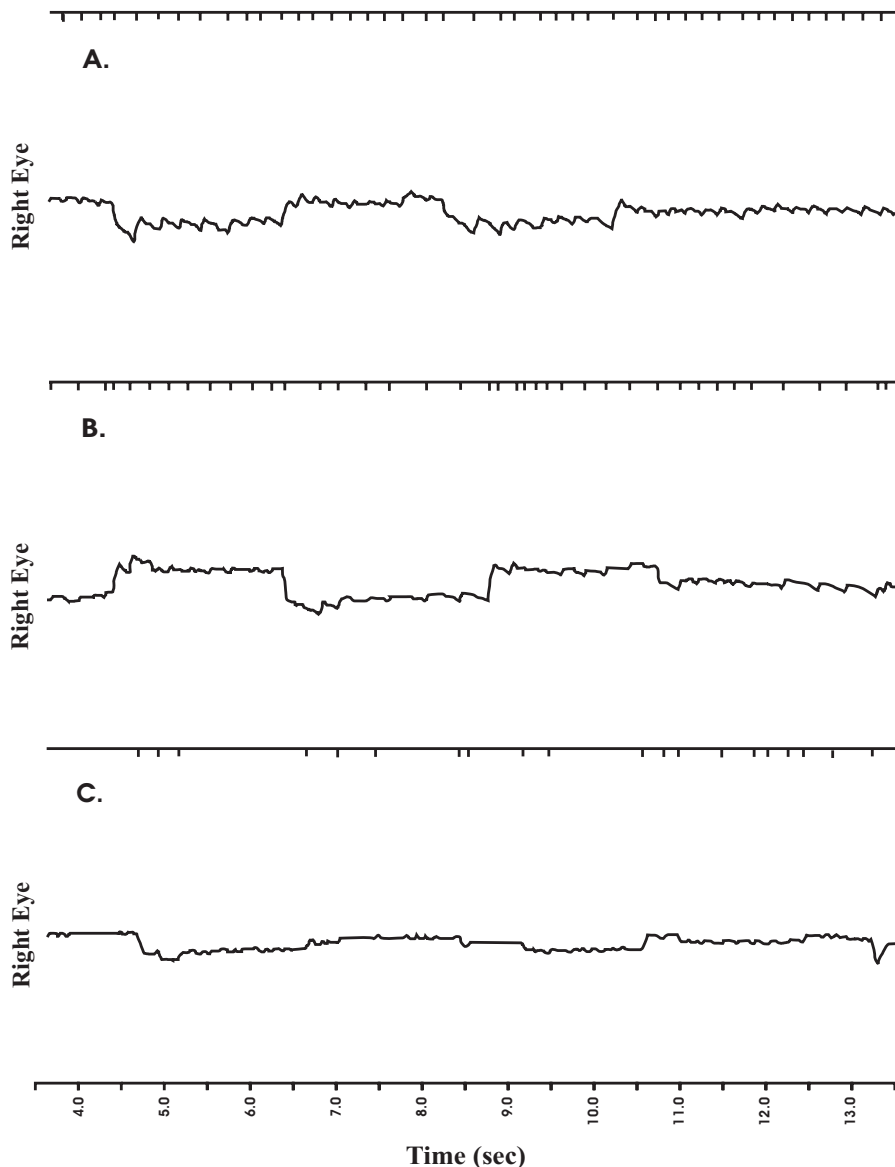


Figure 3. Horizontal eye position as a function of time. Binocular viewing. Patient is changing fixation every few seconds between 10 degrees left, 10 degrees right, and center. Up=rightward and down=leftward. Small tick marks denote jerks of nystagmus. A = Post-therapy with spectacle lens correction and prisms. B = Post-therapy with spectacle lens correction and soft contact lenses. C = Post-therapy with spectacle lens correction, prisms, and soft contact lenses.

3A), there was little change in either frequency or amplitude of the nystagmus. However, with the spectacle correction and soft contact lenses (Figure 3B), there was little change in nystagmus frequency, but noticeable reduction in nystagmus amplitude. With the combination of the soft contact lenses and the prism in conjunction with the spectacle correction (Figure 3C), however, there was a marked decrease in both nystagmus frequency and amplitude. Full analysis of the objective eye movement findings is shown in Table 2, outlining the frequency changes in the nystagmus that occurred with the various optical treatment and gaze angle combinations.

DISCUSSION

The detailed findings of this relatively complex case study clearly demonstrates considerable improvement over a range of sensory and motor functions following four months of multimodal optometric vision therapy in a patient with congenital nystagmus and constant exotropia. Most notable improvements were in visual acuity (i.e., 20/70 to 20/40 monocularly and 20/50 to 20/40 binocularly), eye movements (i.e., reduced nystagmus frequency and amplitude), and binocularity (e.g., change from tropia to phoria at near). This is consistent with other case studies using either single mode^{13,14,16-19} or multi-

modal¹⁵ forms of conventional optometric vision therapy. Earlier ophthalmological intervention (i.e., extraocular muscle surgery) in this patient had only minimal and transient impact with respect to both the exotropia and nystagmus.

In addition to the manifold improvements evident in the basic clinical test findings, other gains were noteworthy. First, and most importantly, the positive effects of optometric vision therapy allowed DH to attain his long sought personal goal, namely attainment of a driver's permit. Second, besides the sense of accomplishment, the ability to drive rather than be driven provides him with a new degree of independence, as well as fulfillment of an important expectation of most teenagers. Third, DH has significantly increased control over his nystagmus, and hence improved cosmesis and related self-esteem. At times, the nystagmus is barely perceptible. DH will continue with his vision therapy program for possible additional vision enhancement, as well as maintenance of the current vision gains. DH will also have the prism ground into his new spectacle prescription (OD: +0.25D/-6.00Dx025; OS: -0.25D/-3.75Dx155), which was reduced from 5 PD to 3 PD BI over each eye. This should provide a further small improvement to his visual acuity based on the trial frame results (Table 1). Unfortunately, at this time, he declined use of the contact lens prescription despite their positive visual sensory and motor impact, but this will be suggested again in the future. Most interestingly, it was with the combination of all three optical components, namely the spectacle correction, prism, and soft contact lenses, that produced a marked reduction in both the nystagmus frequency and amplitude, thus suggesting an additive effect that should be considered in similar patients.

An interesting attribute of this case study was the family lineage of nystagmus, who also manifested exotropia and high astigmatism. This inheritance pattern appears to be autosomal dominant with incomplete penetrance (Figure 1), based on personal accounts of those in the family that also have the same primary anomalies and genetic research comparisons.⁹ The genetic linkage can be traced as far back as DH's great-grandfather, with multiple descendants expressing the trait. There is the possibility that other

family members also carry and express this gene with much less penetrance, and hence have not been identified. This is of importance in the area of genetic counseling concerning both DH and other family members for future expectations of this pattern continuing to be passed down through the generations.

CONCLUSION

This case study demonstrates the effectiveness of multimodal vision therapy in congenital nystagmus. The use of full spectacle refractive correction, prisms, and conventional optometric vision therapy allowed DH to improve his visual acuity sufficiently to attain his primary goal of obtaining a driver's permit. The specific program of optometric vision therapy also improved DH's binocular status and cosmesis due to enhanced oculomotor control. Objective eye movement recordings confirmed both the clinical measurements and impressions, as well as subjective observations. Furthermore, it permitted direct visualization of the combined effect that the treatment conferred upon the general oculomotor control.

Acknowledgements

We thank Chris Maggio, Dr. C.L. Mellinger and staff at Eye Care Associates, and patient DH and family for their assistance in this case.

None of the authors have a financial or other interest in products of Computer Orthoptics or Instructional/Communications Technology Inc.

References

1. Leigh RJ, Zee DS. *The Neurology of Eye Movements*, 3rd ed. New York: Oxford Press, 1999.
2. Ciuffreda KJ, Tannen B. Training of nystagmus: a multi-sensory approach. *J Behav Optom* 1999;10:63-6.
3. Bedell HE, Bollenbachs MA. Perception of motion smear in normal observers and in persons with congenital nystagmus. *Invest Ophthalmol Vis Sci* 1996;37:188-95.
4. Ciuffreda KJ, Goldrich SG, Neary C. Use of eye movement auditory biofeedback in the control of nystagmus. *J Am Optom Assoc* 1982;51:615-7.
5. Ishikawa S, Tanakadate A, Nabatame K, Ishu M. Biofeedback treatment of congenital nystagmus. *Neuro-ophthalmol Jpn* 1985;2: 58-64.
6. Mezawa M, Ishikawa S, Ukai K. Changes in waveform of congenital nystagmus associated with biofeedback treatment. *Brit J Ophthalmol* 1990;74: 472-6.
7. Rhee DJ (editor). *The Wills Eye Manual*, 3rd ed. Boston: Wolters Kluwer Company, 1999.
8. Gottlob I. Nystagmus. *Curr Opin Ophthalmol* 2001;12: 378-83.
9. Oetting WS, Armstrong CM, Hollschau AM, DeWan AT, Summers CG. Evidence for genetic heterogeneity in families with congenital motor nystagmus. *Ophthalmic Genetics* 2000;21: 227-33.
10. Ciuffreda KJ, Tannen B, Rutner D. Multi-sensory feedback therapy for oculomotor dysfunction. In: Hung GK, Ciuffreda, KJ, eds. *Models of the Visual System*. New York: Kluwer Academic/Plenum Publishers, 2002.
11. Ordonez XP, Ciuffreda KJ. Reading eye movements in patients with nystagmus and proposed therapeutic paradigms. *J Behav Optom* 1997;8:99-103.
12. Von Noorden GK. *Binocular Vision and Ocular Motility: Theory and Management of Strabismus*. St. Louis: Mosby, 1980.
13. Healy E. Nystagmus treated by orthoptics. *Am J Orthopt* 1952;2:53-5.
14. Healy E. Nystagmus treated by orthoptics: a second report. *Am J Orthopt* 1962;12:89-91.
15. Leung V, Wick B, Bedell HE. Multifaceted treatment of congenital nystagmus: a case report of six cases. *Optom Vis Sci* 1996;73: 114-24.
16. Pearlman CA. A case study. *J Am Optom Assoc* 1976;47:396-8.
17. Stohler T. Afterimage treatment in nystagmus. *Am Orthop J* 1973;23:65-7.
18. Smith WS. *Clinical Orthoptics Procedure*. St. Louis: Mosby, 1950.
19. Taylor EA. *The Fundamental Reading Skill*. Springfield, Ill.: Charles C. Thomas Publishers, 1966.
20. Abadi RV. Visual performance with contact lenses and congenital idiopathic nystagmus. *Brit J Physiol Opt* 1979;33:32-7.
21. Abrams BS. Correcting nystagmus with corneal lenses. *Optom Wkly* 1955;46: 809-12.
22. Allen ED, Davies PD. Role of contact lenses in the management of congenital nystagmus. *Brit J Ophthalmol* 1983;67:34-836.
23. Dell'Osso LF, Traccis S, Abel LA, Erzurum SI. Contact lenses and congenital nystagmus. *Clin Vis Sci* 1988;3:229-32.
24. Matsubayashi K, Fukushima M, Tabuchi A. Application of soft contact lenses for children with nystagmus. *Neuro-ophthalmol* 1992;12: 47-52.
25. Stevenson RW. The application of contact lenses to nystagmus. *Optics(Scotland)* 1975; June: 4-8.
26. Blekher T, Yamada T, Yee RD, Abel LA. Effects of acupuncture on foveation characteristics in congenital nystagmus. *Brit J Ophthalmol* 1998;82: 115-20.
27. Dell'Osso LF, Leigh RJ, Daroff RB. Suppression of congenital nystagmus by cutaneous stimulation. *Neuro-ophthalmol* 1990;11:173-75.
28. Sheth NV, Dell'Osso LF, Leigh RJ, Van Doren CL, Peckham HP. The effects of afferent stimulation on congenital nystagmus foveation periods. *Vis Res* 1995;35:2371-82.
29. Hogan RW. *PDR Pocket Guide to Prescription Drugs*. New York: Simon and Shuster Adult Publishing Company, 2001.
30. Griffin JR, Grisham JD. *Binocular Anomalies: Diagnosis and Vision Therapy*, 3rd ed. Boston: Butterworth-Heinemann, 1995.
31. Schieman M, Wick B. *Clinical Management of Binocular Vision*. Philadelphia: Lippincott, Williams and Wilkens, 1994.
32. Press LJ. *Applied Concepts in Vision Therapy*. St. Louis: Mosby, 1997.
33. Ciuffreda MA, Ciuffreda KJ, Santos, D. Visagraph baseline analysis and procedural guidelines. *J Behav Optom* 2003;14:60-4.

Sources

- a. Computer Orthoptics; R.C. Instruments, Cicero, IN.
- b. Instructional/Communications Technology Inc., Huntington Station, NY.

Corresponding author:

Kenneth J. Ciuffreda, O.D., Ph.D.
SUNY/State College of Optometry
Department of Vision Sciences
33 West 42nd Street
New York, NY 1003
kciuffreda@sunyopt.edu
212-780-5132

Date accepted for publication:
November 28, 2003