

# REHABILITATIVE OPTOMETRIC MANAGEMENT OF A TRAUMATIC BRAIN INJURY PATIENT

LYNN FISHMAN HELLERSTEIN, O.D.  
SIEGLINDE FREED, M.S.

## Abstract

*Patients with traumatic brain injury (TBI) frequently exhibit visual symptomology characterized by diplopia, intermittent blurriness, asthenopia, photophobia, and spatial disorientation. Clinical findings on this patient population commonly include accommodative and binocular dysfunctions, refractive error shifts, and oculomotor dysfunction. Resultant visual field loss in many of these patients also impacts visual performance.*

*We present a case history of a TBI patient with associated visual dysfunction. Treatment modalities included lenses, prisms, and rehabilitative vision therapy. Improvements in function and visual processing were noted and clinically documented in the visual evaluation and visual electrodiagnostics.*

## Key Words

*traumatic brain injury (TBI), visually evoked cortical potential (VECP), electroretinogram (ERG), contrast sensitivity testing*

**T**raumatic brain injury (TBI) patients show many types of visual dysfunction, including accommodative, binocular and oculomotor dysfunction, refractive error shift, and visual field loss.<sup>1-16</sup> These visual problems have great impact on everyday functioning and daily living activities, such as reading, driving, localizing, eye-hand coordination activities, etc. Much of the literature regarding visual dysfunction in TBI concentrates on moderate to severe injuries. A patient with a mild TBI, as diagnosed by a neurologist or neuropsychologist, can show significant functional deficit, even in the absence of loss of consciousness at time of injury.<sup>17</sup> In fact, whiplash or cervical strain can cause visual dysfunctions without a documented TBI.<sup>18-20</sup> Mild TBI encompasses a diffuse injury which can disrupt the overall speed, efficiency, and integration of mental and central nervous system function.

Optometrists have historically treated functional and visual perceptual problems in children and adults.<sup>2,12,21</sup> Therefore, it is appropriate for optometric services to be included in the rehabilitation of the TBI patient with visual problems.<sup>1,2</sup>

We present a case history of a patient with a mild TBI. This 32-year-old white female had been evaluated by several ophthalmologists prior to our evaluation. She received no vision treatment other than the recommendation to "buy a pair of magnifiers at the drug store."

## History

The patient presented for examination approximately two and one half years after a fall, which resulted in a mild traumatic brain injury, whiplash, and cervical strain, as diagnosed by her neurologist. She complained of frequent frontal headaches which occurred one or two times per week, horizontal intermittent diplopia, blurred vision, motor function decrease, poor balance, attention/concentration and organizational deficits. She stated that she experienced difficulties with performance of daily tasks, i.e., grocery shopping, cooking, and writing. General medical health was unremarkable, with no known allergies to medications. She was taking Depacote (250 mg) and Ibuprofen. Family history indicated that her father had Diabetes Mellitus Type II. There was no history of previous eye or head trauma and the social history was unremarkable.

## Visual Evaluation

Visual evaluation of the patient is based upon the standard optometric primary care examination. However, tests are added to probe pertinent areas for the TBI patient. Consequently, additional testing includes contrast sensitivity, Goldmann visual fields, and perceptual/motor tests. Electrodiagnostic testing, which can objectively document visual system deficit, including visually evoked cortical potential (VECP), and the focal and full-field electroretinogram (ERG) are also performed. The VECP reflects not only the neural repre-

sensation of retinal function, but also indicates the functional integrity of the visual pathway from the retina to and including the visual cortex. The full-field ERG represents an overall score of retinal function and the focal ERG response indicates macular receptor integrity.

The initial clinical findings follow:

### Ocular Health

External Examination: Unremarkable for both eyes and adnexa

Pupils: Equal, round, and respond to light and accommodation; no Marcus Gunn response

Slit Lamp Biomicroscopy: Unremarkable for both eyes

Intraocular Pressures: 12 mm Hg OU by applanation tonometry

Dilated Fundus Examination: Cup/Disc ration of 0.2 OU, normal macular and foveal areas, intact vascular tree OU, no pathology in retinal peripheries

### Visual Acuity

Distance: OD 20/20, OS 20/25

Near: OD 20/30, OS 20/60 at 16 inches. It is important to note that by the end of the examination, the visual acuity of the left eye decreased to 20/200.

### Distance Refraction

Static Retinoscopy: OD +2.50 D and OS +2.00 D

Subjective: There was a variable acceptance from Plano to +1.00 D (20/20) for the OD. The refraction of the OS was Plano (20/25-). Because of the variability

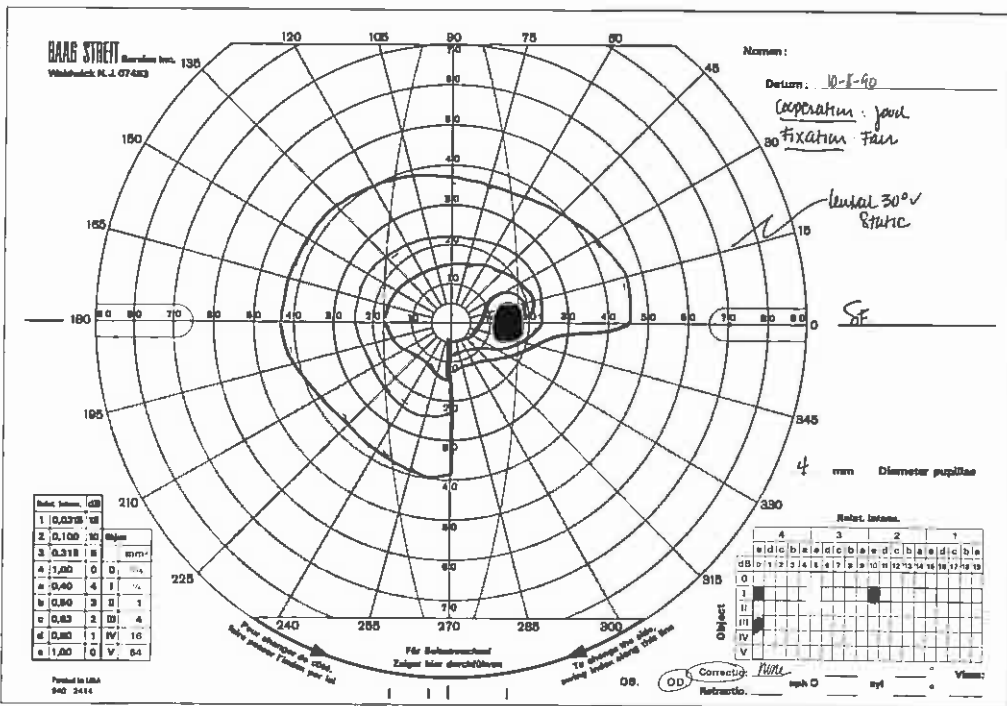


Figure 2a. Initial Goldmann Visual Field, O.D.

in refraction, the patient was given +1.00 D spheres OU to wear for five minutes and then was retested. Delayed subjective (gross findings) was OD +1.50 D (20/20), OS +1.00 D (20/25-). Cycloplegic testing utilizing 1% cyclopentolate revealed: Retinoscopy: OD +2.50, OS +2.00 D. Subjective: OD +2.75 D (20/20), OS +2.25 D (20/25).

### Sensorimotor Examination

Cover Test Distance: Orthophoria  
Cover Test Near: 10 prism diopters of intermittent alternating exotropia  
Nearpoint of Convergence: 10"/14"  
Distance Vergences:

Convergence - X/6/2

Divergence - 12/6

Near Vergences: Testing not possible because of diplopia at near

Accommodative Status: Positive and negative relative accommodation--testing not accomplished because of diplopia

Dynamic near retinoscopy: OD variable reflex, +2.00 D to +3.00 D; OS +0.75 D (dull reflex)

Flexibility: Inability to clear +/- 2.00 flipper, monocularly--binocular testing impossible because of diplopia

Cheirosopic Tracings, Van Orden Star, and Brock String Testing: All of these tests revealed fragile binocular integration because of alternating central to complete suppression.

Fixation Disparity (utilizing Wesson Fixation Disparity Card)<sup>a</sup>: 8.6 to 12.9 minutes of arc, exo deviation, with instability and alternating suppression. While base-in prism reduced the exo deviation, the associate phoria could not be determined because of the instability and suppressions. Ocular Motilities: Pursuits and saccadic fixations: Concomitant with full excursions in all fields of gaze, but with frequent loss of rapport with the target. The patient demonstrated tearing and discomfort during this testing and saccades could not be performed without head movement.

### Contrast Sensitivity Testing

Contrast sensitivity testing was performed utilizing the Vistech CTS 6500 System.<sup>b</sup> Initial contrast sensitivity function abnormalities was found to be subnormal in low, middle, and high spatial frequencies for both eyes (see Figure 1).

### Visual Perceptual/Motor Testing

Developmental Test of Visual Motor Integration<sup>c</sup>: The patient could adequately copy 21 of the 24 forms. The patient took an inordinate amount of time to complete this test. Observations of patient's behavior included blinking, squinting and body readjustments to move closer and further from the paper.

Test of Visual Perceptual Skills<sup>d</sup>: Unable to complete testing at the time due to ocular discomfort and fatigue.

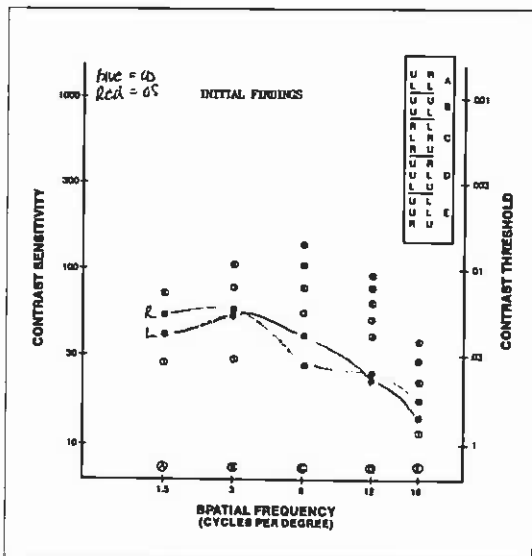


Figure 1. Initial Contrast Sensitivity Findings

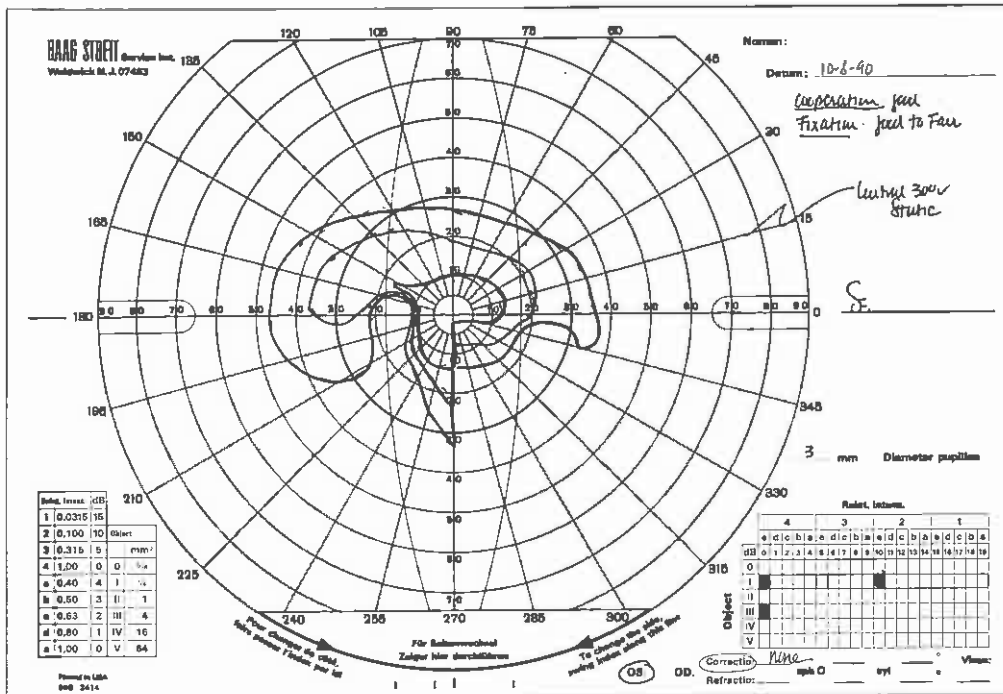


Figure 2b. Initial Goldmann Visual Field, O.S.

**Localization:** The patient could not accurately grasp or point to objects within arm's reach. Her grasp was consistently several inches behind the object.

**Walking/Balance:** The patient needed assistance in walking long distances because of fatigue and poor balance. She could not walk heel-toe on a straight line.

### Goldmann Visual Field Testing

Initial Goldmann visual field testing results showed a generalized constriction of the peripheral isopters for both eyes utilizing the III/4e target. There was a homonymous, incongruous lower right quadrantanopsia with III/4e, I/4e and I/2e target intensities. There was also baring of the physiological blindspot on the left side (see Figures 2a, 2b).

### Visual Electrodiagnostic Testing

Visual electrodiagnostic testing was performed using pattern-reversal stimulation from a television monitor at an intensity of between 68 and 96 nit/seconds. Stimulations were performed binocularly and to each eye independently. The stimulus subtended a visual angle of 0-14 degree radius with a variety of check sizes from 1 degree 56 minutes to 11 minutes. The visually evoked cortical potential (VECP) was always recorded from both hemispheres using standard bi-polar linkage O2-C4 and O1-C3 and midline recording as well as using FpZ to Cz to Oz. This technique allows lateralization of the evoked poten-

tial over the visual cortex contralateral to the field illuminated.<sup>22-24</sup> The resulting signal was recorded and averaged using computer and clinical averages.

Three trials of 100 rps were performed for the purposes of waveform reproducibility and to determine processing stability and conduction quality in this patient. In the normal VECP recording, multiple trials generally reveal reproducible and consistent waveform responses. TBI patients can demonstrate loss of conduction speed and quality over time in multiple trials. The latency was defined as a measure of time it takes for visual information to be processed from the eye to the visual cortex. The interwave amplitude represented the quality of conduction through the anterior visual pathways.

Initial VECP findings for this patient showed normal waveform values for both sides in the first trial. The second trial showed P100 latency delays with decreased interwave amplitude responses for the left side and normal latency values and a decreased interwave

amplitude for the right. The third trial demonstrated no consistent or organized waveform responses for the left side and delays in P100 latency values and further decreased interwave amplitude responses for the right (see Figure 3). Full field ERG and focal ERG findings were found to be unremarkable for both eyes.

### Diagnoses

1. Mild traumatic brain injury, by history
2. Hyperopia
3. Intermittent near exotropia
4. Accommodative dysfunction
5. Binocular dysfunction
6. Oculomotor dysfunction
7. Normal retinal and macular function
8. Homonymous, incongruous, lower right quadrantanopsia
9. Abnormal conduction through the anterior visual pathways. The abnormality was greater on the left side than the right.

### Management

We prescribed +1.00 D OU for distance. Equal spheres were prescribed because of variability in refraction and because the patient was most comfortable with this prescription. A near prescription of +2.00 D, combined with two prism diopters base-in OU, were given, based on near retinoscopy and patient acceptance. Because of logistics and personal issues for the patient, rehabilitative vision therapy was commenced approximately one year after initial examination. Rehabilita-

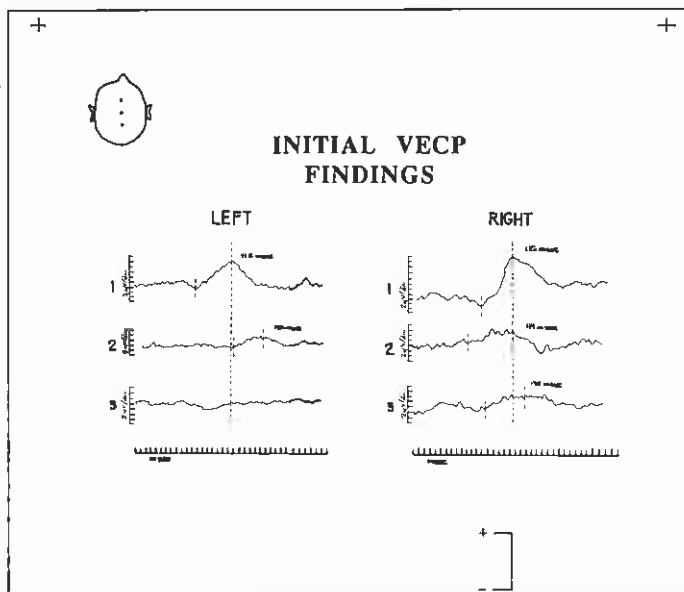


Figure 3. Initial VECP Findings

tive vision therapy was initiated on a one-time-per-week basis, with home therapy activities given. The therapy plan progressed from equalizing monocular oculomotor skills to improving fusional vergences, increasing accommodative flexibility, and eliminating suppression. In order to improve ocular motor control, tasks requiring proprioceptive responses were utilized. Spatial awareness, localization and balance/movement activities were also emphasized. Yoked prisms, walking rails, balance beams, and mini trampolines were used cautiously to allow her to explore movement through space under different conditions and demands. Due to her balance and movement difficulties, consultations with an occupational therapist and referral to a physical therapist were made. Visualization activities including tachistoscope flash and parquetry block series were utilized. Once vision therapy was initiated, she was consistent in attendance and worked well on home therapy activities with her husband's guidance and support.

Throughout the therapy, yoked prisms were investigated and found to be useful, especially in aiding localization ability and spatial awareness. The yoked prisms are based on a number of factors, especially central/peripheral processing, and are worn during visual motor performances to determine effectiveness.<sup>21,25,26</sup> Both distance and near prescriptions were changed to include two prism diopters of base-up yoked prisms.

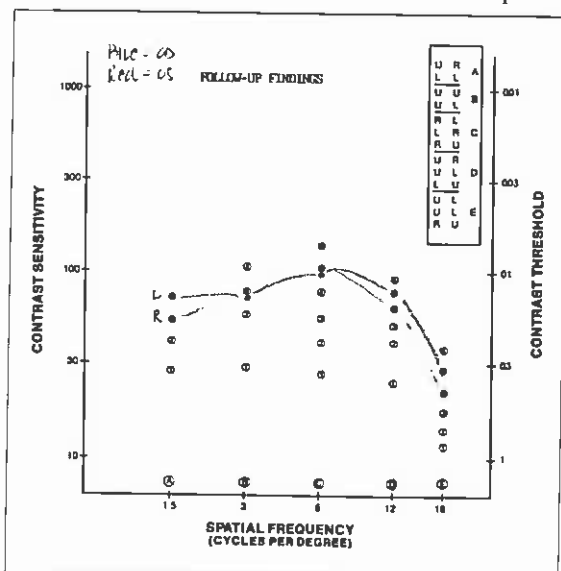


Figure 4. Follow-up Contrast Sensitivity Findings

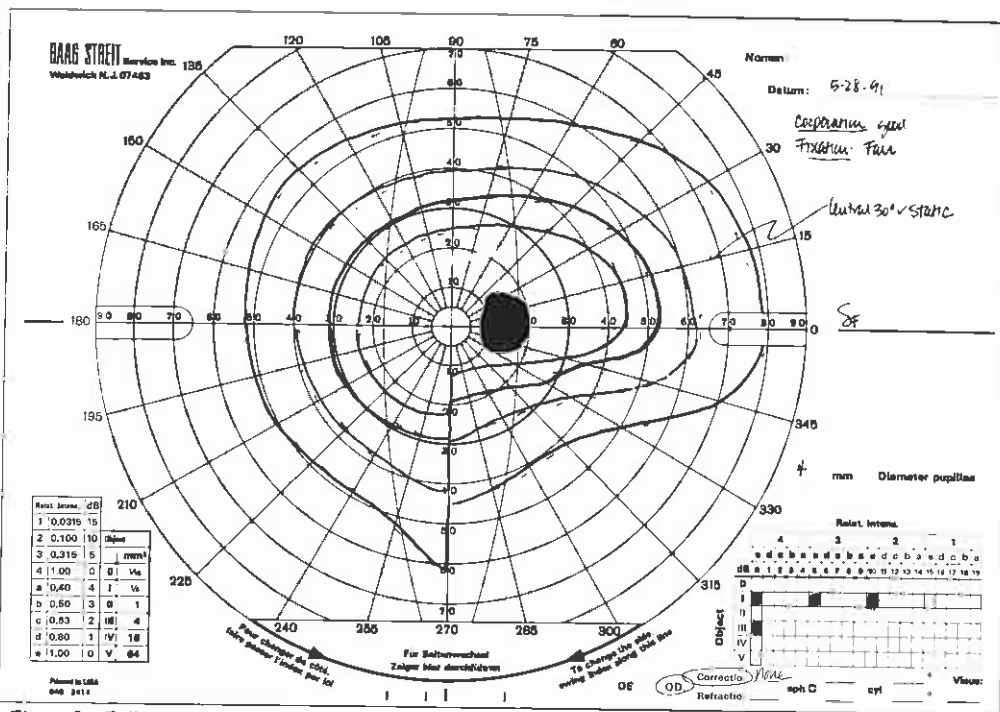


Figure 5a. Follow-up Goldmann Visual Field, O.D.

Diagnostic reevaluation approximately eight months after therapy revealed the following: Improvement in subjective symptomology; less visual confusion and blurriness, less diplopia, and a decrease in headache frequency and severity. Clinical findings at that time revealed the following:

#### Visual Acuity

Distance and Near: 20/20 consistently with either eye or binocularly

#### Sensorimotor Examination

Cover Test Distance: Orthophoria  
Cover Test Near: 8-10 prism diopters exophoria

Nearpoint of Convergence: 5/8 inches

Distance Vergences:  
Convergence - 16/20/6  
Divergence - 10/6

Near Vergences:  
Convergence - 14/3  
Divergence - 24/17  
Accommodative Status:

Positive relative accommodation - 1.00 diopter  
Negative relative accommodation - 2.00 diopter

#### Contrast Sensitivity Testing

Follow-up contrast sensitivity findings showed normal low spatial frequency response, subnormal middle spatial frequency responses and a high spatial frequency re-

sponse which was found to be with normal limits for both eyes (see Figure 4).

#### Goldmann Visual Field Testing

Subsequent Goldmann visual field results demonstrated negligible peripheral field constriction using the III/4e target intensity. The homonymous, incongruous, lower, right quadrantanopsia was still found with all target intensities (III/4e, I/4e, I/3e, and I/2e) but no baring of the physiological blindspot was found for the left eye (see Figures 5a and 5b).

#### Visual Electrodiagnostic Testing

VECP follow-up evaluation demonstrated first and second trials to be within normal limits for both sides. Third trials showed loss of P100 conduction with decreased interwave amplitude responses for both sides. Findings showed waveform improvement when compared to the initial VECP evaluation for this patient (see Figure 6). Retinal function was found to be unchanged and still within normal limits for both eyes.

Rehabilitative vision therapy was continued for another 18 months with sporadic interruptions due to patient compliance problems. At the last optometric progress evaluation, the patient reported being able to read comfortably for approximately 45 minutes. She can drive and perform most daily tasks. She stated that she is still unable to work outside the home, mainly due to her fatigue. She reports that her visual complaints have

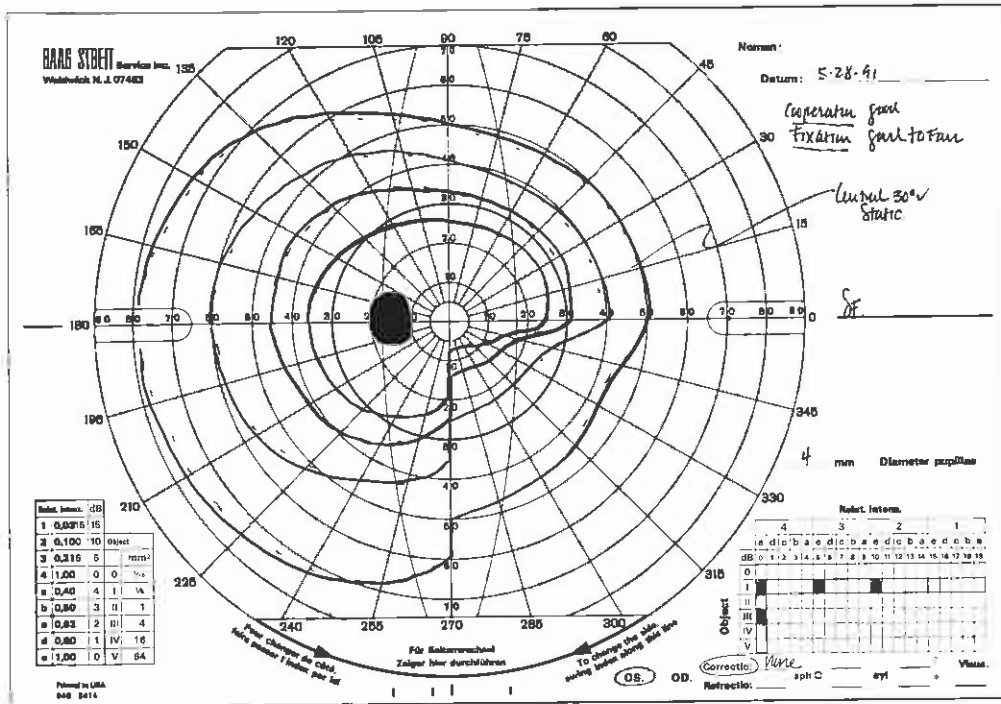


Figure 5b. Follow-up Goldmann Visual Field, O.S.

drastically decreased, but are more noticeable when she is fatigued. The patient still utilizes her distance and near prescriptions.

### Conclusion

It has been well-documented that visual system dysfunction is frequently found in patients with TBI.<sup>1-16</sup> In-depth vision evaluation and examination are critical when assessing the injury extent to the visual system in this population. In patients with mild to moderate TBI the probability of chiasmal compressions or damage is low, but the possibility of post-chiasmal and, more usually, cortical damage is higher. By recording from right and left occiputs independently, it is possible to identify post-chiasmal damage.<sup>27,28</sup> We found an initial breakdown in visual processing in this patient over three trials for each side with subsequent improvement in follow-up electrophysiological evaluation. This patient's subjective visual complaints had a correlate in documented and verified VECF pathway abnormalities. VECF findings demonstrated waveform improvement on both sides after approximately eight months of rehabilitative vision therapy. VECF assessment of this patient with TBI was of significant clinical use in determination of visual pathway processing integrity.

The presented case history is consistent with symptomology encountered in this population. The term "mild TBI" is very misleading and does not necessarily trans-

late to "mild functional loss," as these injuries can have a devastating impact on function. It is also interesting to note that treatment was initiated approximately two-and-one-half years after injury and eliminates "spontaneous recovery" as an explanation for improvement in this patient's visual system deficits. The treatment was found to yield improvement in visual and overall functioning for this patient. The improvements were not only documented in optometric clinical findings but also in the electrodiagnostic and contrast sensitivity test results as well.

### References

- Cohen AH, Rein LD. The effect of head trauma on the visual system: the doctor of optometry as a member of the rehabilitation team. *J Am Optom Assoc*, 1992; 63: 530-536.
- Gianutsos R, Ramsey G. Enabling rehabilitation optometrists to help survivors of acquired brain injury. *J Vis Rehabil*, 1988; 2 (1): 37-58.
- Gianutsos R, Ramsey G, Perlin R. Rehabilitative optometric services for survivors of acquired brain injury. *Arch Phys Med Rehabil*, 1988; 69: 574-578.
- Rosenthal M et al. Rehabilitation of the adult and child with traumatic brain injury. Philadelphia: F. A. Davis Co., 1990: 351-365.

- Fraco RF, Fells P. Ocular motility problems following road traffic accidents. *Brit Orthopt J*, 1989; 46 (40): 40-48.
- Padula WV. Neuro-optometric rehabilitation for persons with a TBI or CVA. *J Optom Vis Dev*, 1992; 23: 4-8.
- Mazow ML, Tang R. Strabismus associated with head and facial trauma. *Am Orthop J*, 1982; 32: 31-35.
- Harrison RJ. Loss of fusional vergence with partial loss of accommodative convergence and accommodation following head injury. *Binoc Vis*, 1987; 2 (2): 93-100.
- Stanworth A. Defects of ocular movement and fusion after head injury. *Brit J Ophthal*, 1974; 58 (3): 266-271.
- Pratt-Johnson JA. Central disruption of fusional amplitude. *Brit J Ophthal*, 1973; 57 (5): 347-350.
- Beck RW. Ocular deviation after head injury. *Am Orthop J*, 1985: 103-107.
- Aksionoff EB, Falk NS. The differential diagnosis of perceptual deficits in traumatic brain injury patients. *J Am Optom Assoc*, 1992; 63: 554-558.
- Neetens A. Extraocular muscle palsy from minor head trauma. *Neuro-ophthal*, 1983; 3 (1): 43-48.
- Vogel MS. An overview of head trauma for the primary care practitioner, Part II: Ocular damage associated with head trauma. *J Am Optom Assoc*, 1992; 63: 542-546.
- Tierney DW. Visual dysfunction in closed head injury. *J Am Optom Assoc*, 1988; 59 (8): 614-622.
- Fowler MS, Richardson AJ, Stein JF. Orthoptic investigation of neurological patients undergoing rehabilitation. *Br. Orthopt J*, 1991: 48.
- Kay T. Minor head injury: an introduction for professionals. National Head Injury Foundation, Inc., 1986: 1-12.
- Burke JP, Orton HP et al. Whiplash and its effect on the visual system. *Graef's Arch Clin Exp Ophthal*, 1992; 230: 335-339.
- Wiesinger H, Guerry D. The ocular aspects of whiplash. *Virginia Med Monthly*, 1962; 89: 165-168.

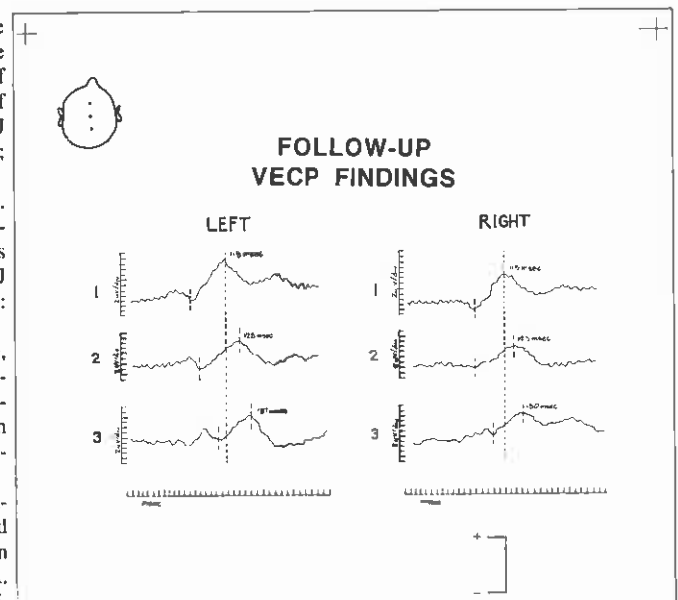


Figure 6. Follow-up VECF Findings

20. Oosterveld WJ, Kortschot HW, Kingma GG, A de Jong HA, Saatci MR. Electronystagmographic findings following cervical whiplash injuries. *Acta Otolaryngol (Stockholm)*, 1991; 111: 201-205.
21. Berne SA. Visual therapy for the traumatic brain-injured. *J Optom Vis Devel*, 12/90; 21: 13-16.
22. Blumhardt LD, Barrett G, Halliday AM. The asymmetries of visual evoked potentials to pattern reversal in one half field and its significance for the analyses of visual field defects, *Brit J Ophthal*, 1977; 61: 454-461.
23. Halliday AM, Harding GFA, Holder GF: Discussion of lateralization of pattern VECF in homonymous field defects. MTP Press: *Evoked Potentials*, 1980: 292-298.
24. Harding GFA. The use of the visual field potential to flash stimuli in the diagnosis of visual field defects. *Visual evoked potentials in man: new developments*. Oxford: Clarendon Press, 1987: 500-508.
25. Kaplan M. Vertical yoked prisms. *Optom Extension Prog*, CII; 51: 1.
26. Kraskin RA. Lens power in action. *Optom Extension Prog*, CII; 54-55: 12.
27. Rubenstein MP, Harding GFA. The scalp topography of the human visual evoked subcortical potential. *Invest Ophthal Vis Sci*, 1980; 19: 318-321.
28. Rubenstein MP, Harding GFA. Components of the visually evoked subcortical potential to flash stimulation in man in EEG and clinical neurophysiology. *Excerpta Medica. International Congress Series*, 1986: 464-474.

### Sources

- a. Wesson Fixation Disparity Card. University Alabama at Birmingham, School of Optometry.
- b. Vistech Contrast Sensitivity Testing. Consultants, Inc., Dayton, Ohio, 1983.
- c. Beery KE, Buktenica NA. The developmental test of visual motor integration. Cleveland, Ohio: Modern Curriculum Press, 1989.
- d. Gardner MF. Test of visual perceptual skills (non-motor). Seattle, WA: Special Child Publications, 1982.

Corresponding author:

Lynn Fishman Hellerstein, O.D.,  
FCOVD, FAAO

6979 S. Holly Circle, Ste. 105

Englewood, CO 80112-1065

Date accepted for publication:

January 4, 1994