

# Article • Limbal Vernal Keratoconjunctivitis: Prompt Treatment Can Prevent Visually Threatening Complications

Denise Alexopoulos, OD • Illinois College of Optometry • Chicago, Illinois

Marilyn Vricella, OD • SUNY State College of Optometry • New York, New York

## ABSTRACT

**Purpose:** Vernal keratoconjunctivitis is a T-cell- and IgE-mediated form of allergic ocular disease that results in itching, mucous discharge, photophobia, foreign body sensation, and other potentially debilitating symptoms. The condition typically presents in the first decade of life in males and has a predilection for warm, dry areas. It is essential that optometrists closely evaluate the anterior segment on all patients, diagnose this condition as early as possible, and manage with age-appropriate medications.

**Case Report:** A five-year-old African American male presented for evaluation with a history of bilateral persistent red, itchy eyes for nearly one year. Corneal evaluation revealed superior limbal concretions, known as Horner-Trantas dots, which would support the diagnosis of vernal keratoconjunctivitis even though minimal eyelid involvement was noted. After unsuccessful resolution of symptoms with compliant use of an antihistamine/mast cell stabilizer ophthalmic solution, the patient was then treated with a fluorometholone 0.1% and cromolyn sodium 4.0%, resulting in a reduction of both symptoms and clinical signs.

**Conclusions:** Limbal Trantas dots without other signs of severe allergic ocular disease are an uncommon manifestation of vernal keratoconjunctivitis. Therefore, when a pediatric patient presents with classic allergic symptoms, it is essential to examine beyond the eyelids. Providing a more comprehensive anterior segment assessment will not only improve quality of life for these young patients, but will help prevent more serious sequelae of this atopic condition.

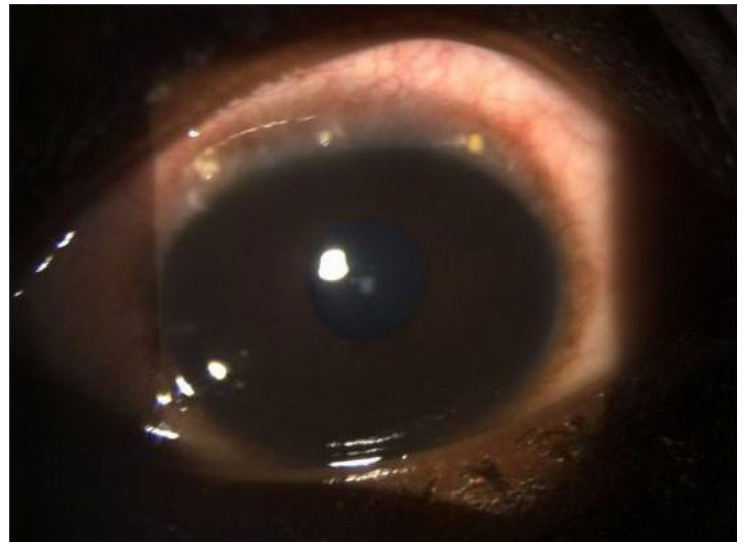
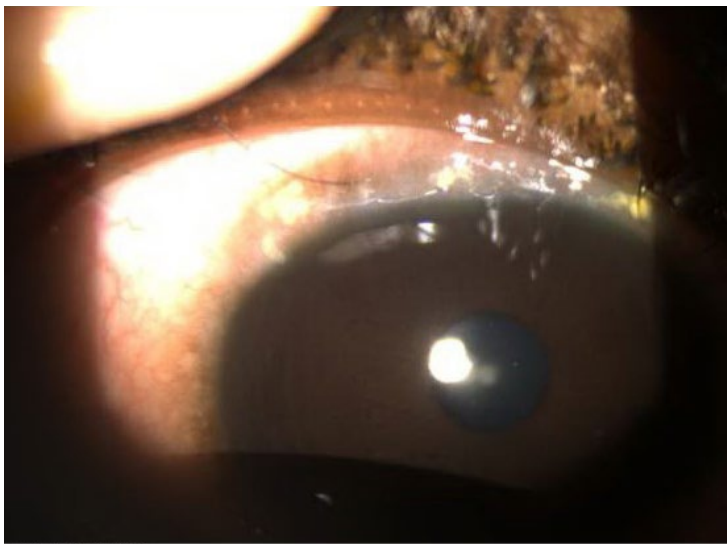
**Keywords:** antihistamine, keratoconus, mast cell stabilizer, vernal keratoconjunctivitis

## Introduction

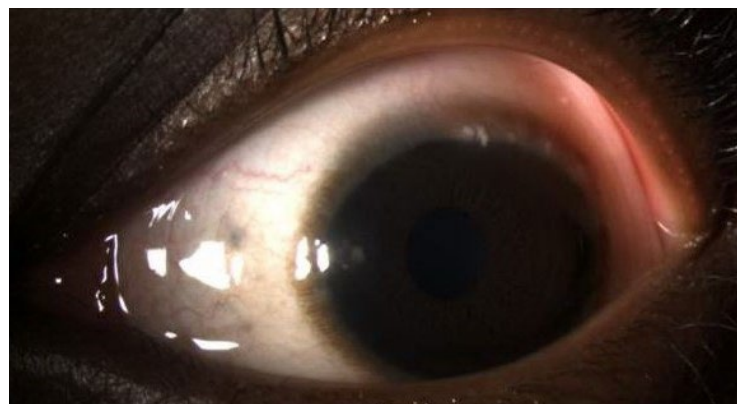
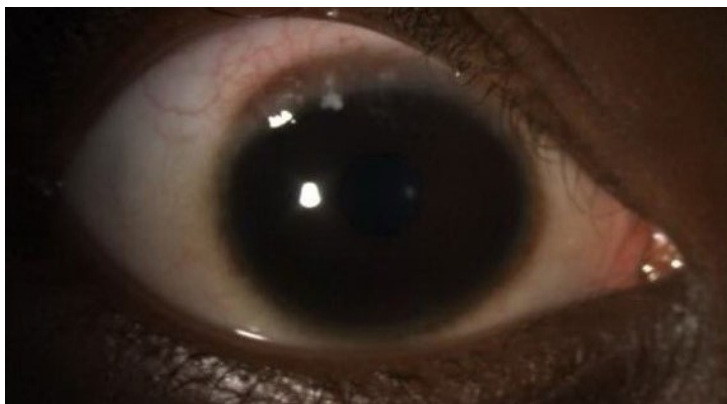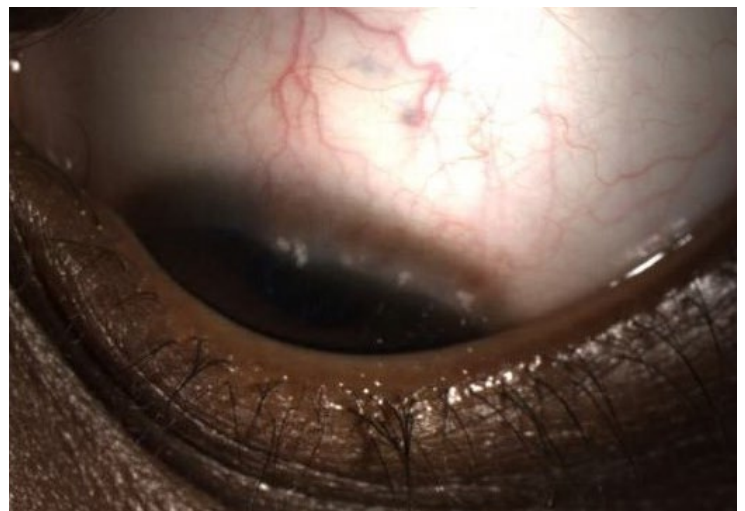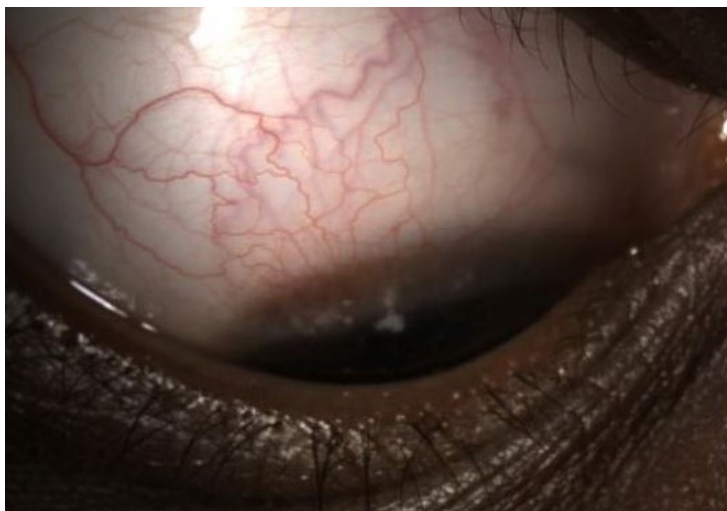Vernal keratoconjunctivitis (VKC) is a T-cell- and IgE-mediated<sup>2</sup> form of allergic ocular disease that typically presents in the first decade of life in males<sup>1-4,8,9,15</sup> and has a predilection for warm, dry areas. Presentation of signs and symptoms may be chronic or seasonal. The most common symptoms include itching, mucous discharge, photophobia, and foreign body sensation. VKC is typically bilateral and may present asymmetrically.<sup>1</sup> There are three classifications of VKC: tarsal, limbal, and mixed.<sup>1-3</sup> The tarsal form is identified by the presence of tarsal cobblestone papillae superiorly.<sup>1</sup> The limbal

form includes an infiltration of eosinophils at the limbus, which may result in limbal papillae, gelatinous thickening, and Horner-Trantas dots.<sup>2,3,16</sup> The mixed form includes both tarsal and limbal involvement. The tarsal and mixed forms are the most common, while limbal VKC is least encountered in clinical practice.<sup>4,5</sup>

While the aforementioned symptoms often gauge the severity of VKC, this condition has potentially sight-threatening sequelae when left untreated or poorly managed. These sequelae include corneal ulcers, known as shield ulcers when associated with VKC, pseudogerontoxon, and punctate epithelial keratitis.<sup>1</sup> In addition, a potential association between VKC and the



**Figure 1.** Limbal concretions on both corneas 2 weeks after initial presentation (OD-left, OS-right)



**Figure 2.** Larger limbal concretions on both corneas after 3 weeks of treatment with ketotifen fumarate 0.025% bid OU

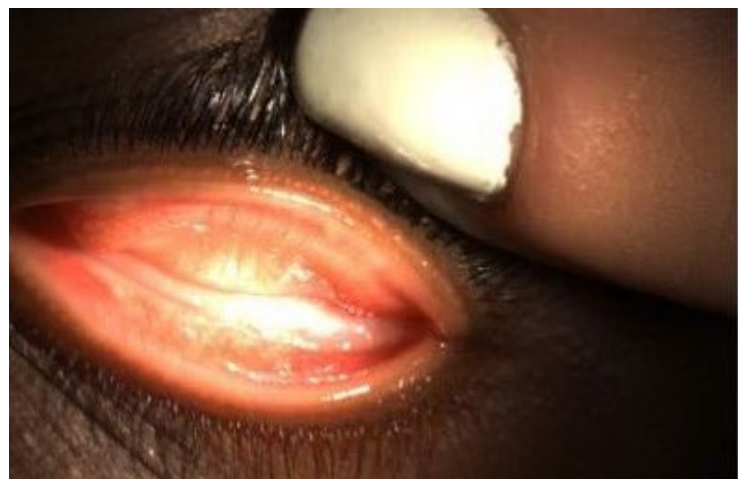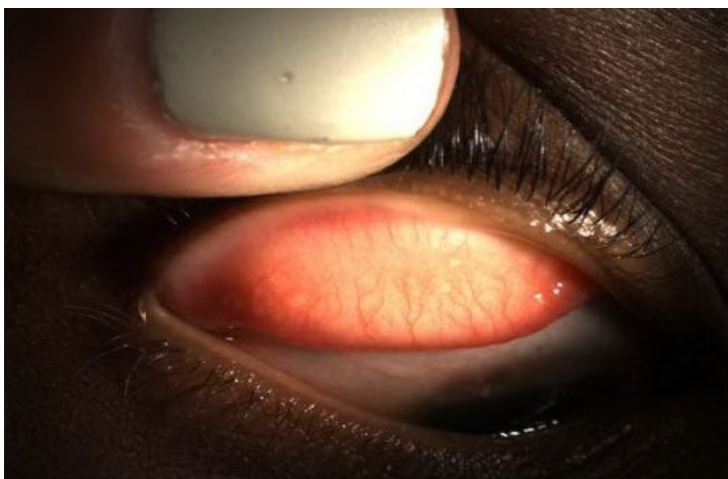
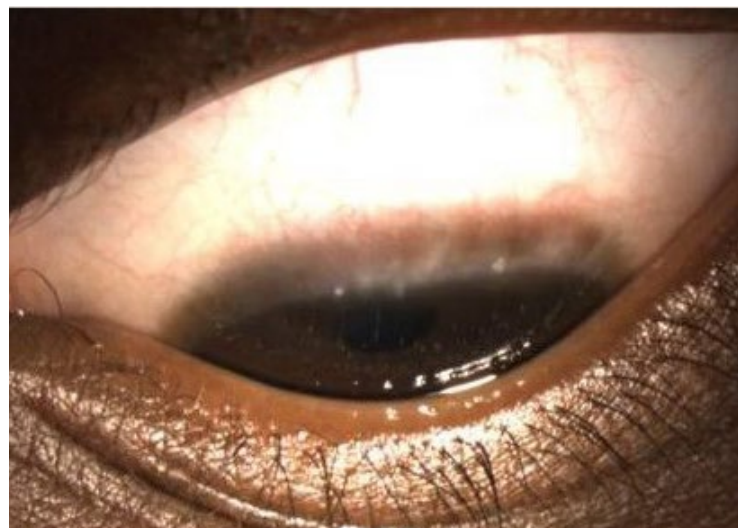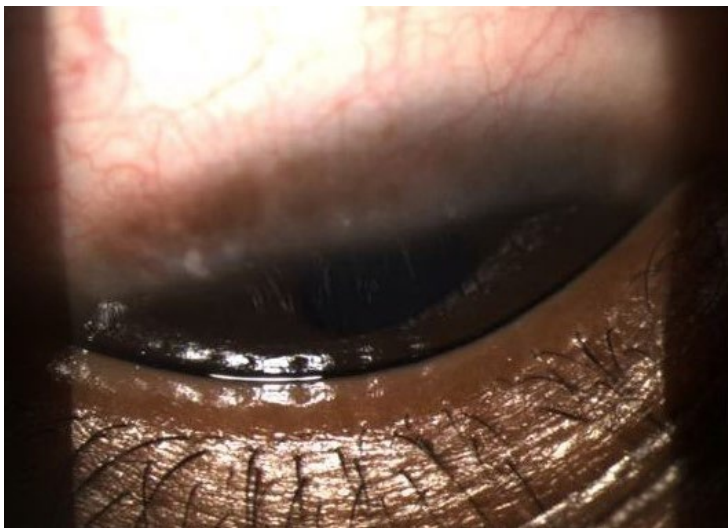
development of corneal ectasia has been reported, although no definitive relationship has yet been established.<sup>9-11</sup>

## Case Report

### Initial Exam

A five-year-old African American male presented for his first comprehensive eye

exam after having failed a vision screening at school. When questioned, the patient's mother reported a history of bilateral red, itchy eyes with vigorous rubbing persisting for approximately six to twelve months. She observed an increase in rubbing during the morning hours, with the right eye being more involved than the left. Treatment at home



**Figure 3.** (Top) Decrease in number and size of limbal concretions bilaterally following four days of treatment with fluorometholone acetate OU. (Bottom) Stable appearance of palpebral conjunctiva bilaterally with minimal papillae.

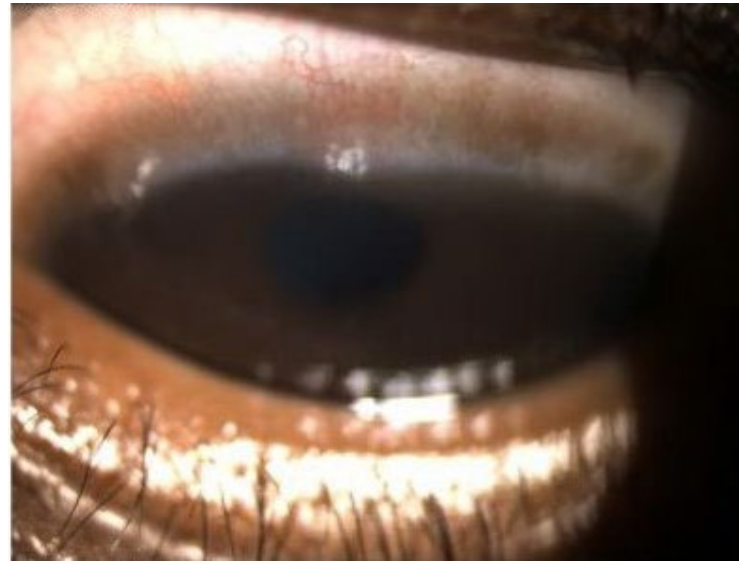
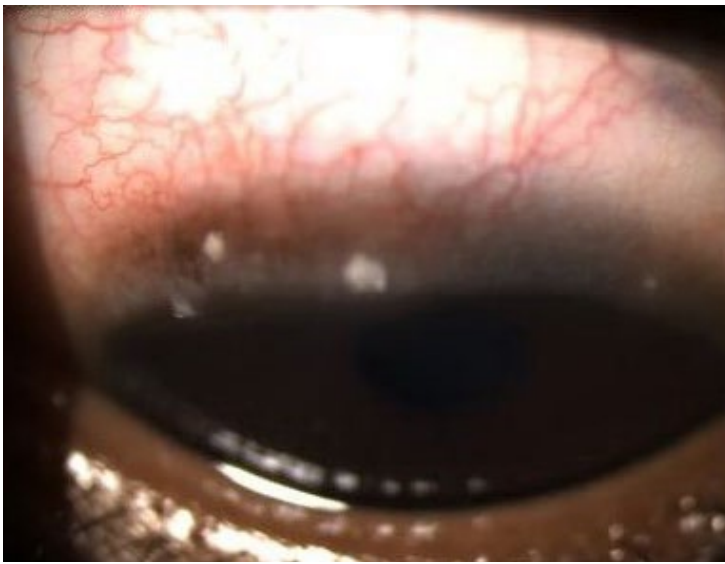
included the eyelids being wiped with a cold washcloth for relief, and symptoms generally improved as the day progressed. There was no history of photophobia, tearing, mucous discharge, or excess eyelid matting upon awakening.

The patient's ocular and medical histories were unremarkable. He used no systemic or topical ophthalmic medications and had not been diagnosed with any allergies or generalized atopic disease. There was no family history of ocular or atopic disease. The patient had been raised in an urban American environment and had never traveled outside the continental United States.

The patient was found to have mild compound hyperopic astigmatism in the left eye greater than the right, with best-corrected visual acuity of 20/20- in each eye.

Pupils, extraocular motility, and confrontation visual fields were all normal. Slit lamp examination showed that the eyelids and eyelashes were clear and free of debris, but trace diffuse bulbar injection was present in both eyes. Lid eversion revealed grade 1-2+ inferior papillae and grade 1+ small superior papillae OU. Multiple 0.5- to 1-mm yellow-white concretions were present on the right superior limbus from 10:00-2:00, and trace to 1+ superficial punctate keratitis was noted on the superior peripheral aspect of both corneas. All other anterior segment findings were normal, as was the patient's dilated posterior segment examination.

Treatment was initiated with ketotifen fumarate 0.025% ophthalmic solution, an H1 antihistamine/mast cell stabilizer combination. The patient's mother was instructed to instill



**Figure 4.** Bilateral decrease in quantity of concretions, increased size of remaining lesions after 2 weeks of steroid treatment and 1 week of cromolyn treatment (OD-left, OS-right)

one drop into each eye every morning and every evening, and the patient was scheduled for a follow-up examination in two weeks.

### **Visit #2 (2 Weeks from Initial Visit)**

After two weeks of compliant treatment, there was slight improvement in objective signs and symptoms. However, the slit lamp examination now confirmed grade 1+ concretions on the superior limbus of both eyes (Figure 1), as compared to the previous visit, when only the right eye had been affected.

Fluorometholone 0.1% (FML), a topical ophthalmic steroid, was added to the patient's treatment regimen with instructions to apply one drop to both eyes four times per day. A baseline intraocular pressure (IOP) using Pulsair non-contact tonometry was 12 mmHg OD and 11 mmHg OS.

### **Visit #3 (3 Weeks from Initial Visit)**

On follow-up, it was reported that due to insurance issues, the pharmacy was unable to fill the FML prescription. However, the use of ketotifen twice per day had continued, and symptoms were stable when compared to the previous visit. Grade 2+ superior limbal concretions OD and grade 1-2+ superior limbal concretions OS were now present (Figure 2).

### **Visit #4 (4 Weeks from Initial Visit)**

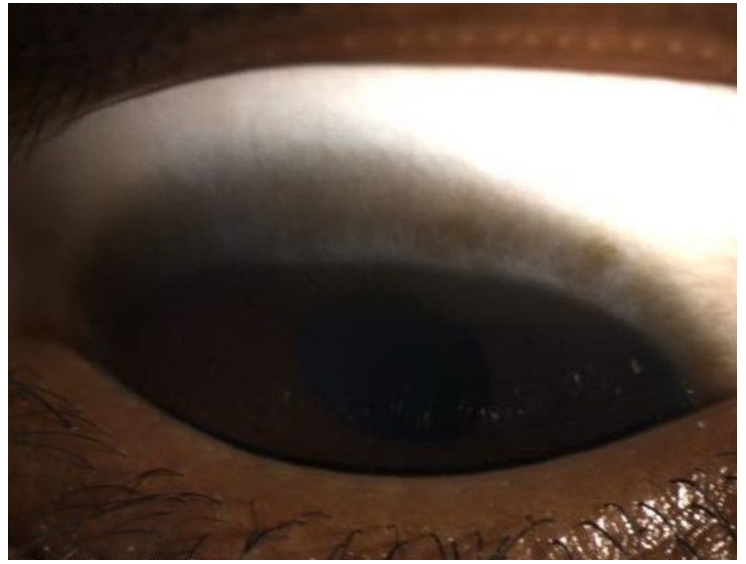
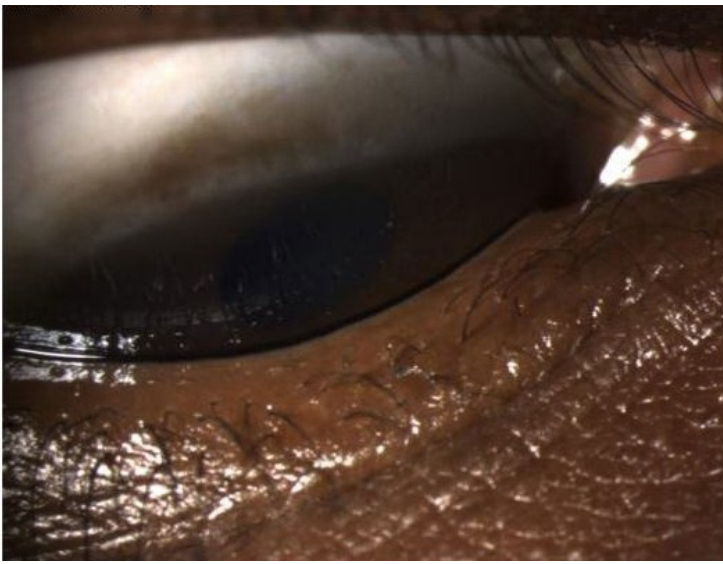
Upon resolution of the insurance issue, the FML was initiated, but for the four days prior to the visit, only two drops per day had been administered to each eye. Compliant use of the ketotifen twice per day in each eye had continued. Further improvement in symptoms was reported at this visit. The severity of the limbal concretions had improved to trace to 1+ OD and trace OS (Figure 3, top). The palpebral conjunctival appearance remained stable with trace papillae (Figure 3, bottom).

FML treatment was continued, and instructions were given to increase compliance with instilling the steroid four times per day in each eye. Ketotifen twice per day was replaced with cromolyn sodium 4.0%, a mast cell stabilizer, four times per day in each eye.

### **Visit #5 (5 Weeks from Initial Visit)**

At this visit, full compliance with both FML and cromolyn four times per day in both eyes was reported. Symptoms continued to improve, although clinical signs did not show ongoing resolution when compared to the previous visit (Figure 4).

IOP measured with Icare tonometry was 17 mmHg in the right eye and 16 mmHg in the left eye, which was 5 mmHg higher in each



**Figure 5.** Complete resolution of limbal concretions bilaterally after 4 weeks of steroid treatment and 3 weeks of cromolyn sodium treatment (OD-left, OS-right)

eye compared to the baseline measurement nineteen days earlier. The authors recognize possible errors from this measurement in that the method used was different than that used for the baseline IOP reading, as well as Icare tonometry potentially overestimating IOP in young patients.<sup>12,13</sup> Also notable is that this measurement may have been artificially elevated as eyelids needed to be held open during measurement.

Since the IOP comparison was limited by the different techniques used for measurement, suspicion for steroid-induced IOP response was low. The same treatment regimen was continued, and the patient was scheduled for a two-week follow-up appointment.

### **Visit #6 (7 Weeks from Initial Visit)**

The patient presented for follow-up and had been using both FML and cromolyn twice per day for two weeks. Understandably, a dosing schedule of four times per day can become difficult to maintain considering family schedules. Conveniently, a complete resolution of symptoms was reported. Clinical examination confirmed this as there were no concretions noted on either limbus (Figure 5), and the mild papillary reaction that had been documented upon initial examination had resolved.

IOP was 20 mmHg in the right eye and 17 mmHg in the left eye with Icare. Undilated direct ophthalmoscopic examination revealed that optic nerve appearance was healthy and stable when compared to the initial visit.

Due to the resolution of both the symptoms and the ocular surface disease, FML was discontinued. Therapeutic instructions were given to use cromolyn four times per day as maintenance therapy and to return for re-evaluation in one month.

### **Visit #7 (5 Months from Initial Visit)**

The patient was lost to follow-up for three months but eventually returned for an anterior segment evaluation and IOP assessment. He continued to be completely asymptomatic; the cromolyn had been discontinued one month prior. The palpebral conjunctiva was free of papillae bilaterally, and neither limbus revealed Horner-Trantas dots.

IOP measured with Icare was 18 mmHg in the right eye and 17 mmHg in the left eye. The patient was instructed to return for comprehensive care one month prior to the start of allergy season so that IOP could be monitored again and cromolyn could be prescribed prophylactically in order to avoid further need for topical steroid therapy.

## Discussion

When evaluating children with bilateral red, itchy eyes, differentials include allergic conjunctivitis, atopic keratoconjunctivitis, VKC, and phlyctenulosis. Diagnosis is based on clinical and laboratory findings.

## Differential Diagnosis

### *Allergic Conjunctivitis*

Seasonal allergic conjunctivitis (SAC) and perennial allergic conjunctivitis (PAC) are IgE-mediated type I hypersensitivity reactions with identical clinical signs, primarily conjunctival chemosis, papillae, and injection.<sup>17</sup> Patients with SAC are allergic to airborne pollens and therefore experience symptoms in the spring and summer. Patients with PAC experience symptoms throughout the year when exposed to perennial allergens such as dust.<sup>17</sup> Although the symptom of pruritis in this case could be considered classic for allergic conjunctivitis,<sup>7</sup> SAC and PAC do not manifest Trantas dots or other types of severe corneal involvement, and therefore these diagnoses were excluded.<sup>4</sup>

### *Atopic Keratoconjunctivitis (AKC)*

AKC differs from allergic conjunctivitis in that it is both an IgE-mediated hypersensitivity reaction and a T-cell-mediated inflammatory condition of the ocular surface.<sup>17</sup> It occurs in patients with atopy who are genetically predisposed to developing allergic reactions.<sup>18</sup> Atopy manifests as conditions such as allergic rhinitis, asthma, dermatitis, and eczema.<sup>17,18</sup> Clinically, AKC can appear similar to VKC. Ocular signs include conjunctival chemosis, injection, and scarring, as well as giant papillae.<sup>17</sup>

In this case, several key factors did not correlate with a diagnosis of AKC. While corneal signs may be present in AKC, they are classically in the form of superficial punctate keratitis due to friction between the palpebral papillae and the corneal surface. In more severe forms, Trantas dots and corneal neovascularization can occur.<sup>14,17</sup> The small area of superior

punctate staining observed was attributed to the underlying concretions and aggressive eye rubbing. Trantas dots were evident, but the papillary reaction observed was considerably milder than in AKC. Above all, there was no reported personal or family history of atopy, making a diagnosis of AKC unlikely.

### *Phlyctenular Keratoconjunctivitis*

Phlyctenular keratoconjunctivitis is a type IV delayed hypersensitivity reaction that results in an inflammatory corneal or conjunctival nodule.<sup>19</sup> This reaction may be secondary to *Staphylococcus* and has been associated with blepharitis.<sup>5</sup> More serious causes include Behcet's disease, tuberculosis, human immunodeficiency virus, and rosacea.<sup>19</sup> There was no suspicion of any of these more insidious causes in a young patient with a lack of systemic symptoms.

Corneal phlyctenules appear initially as small white limbal nodules,<sup>5</sup> which can make them difficult to differentiate from Trantas dots. However, phlyctenules, whether on the cornea or conjunctiva, are vascularized.<sup>5,19</sup> The lesions observed were not notably vascular. Furthermore, a staphylococcal hypersensitivity was unlikely as there was no eyelash scurf or meibomian gland dysfunction present.

## Diagnosis

### *Vernal Keratoconjunctivitis*

The diagnosis of VKC was not immediate, although it was always the primary differential. The lesions resembled concretions rather than the classic gelatinous Horner-Trantas dots, and the papillae were small rather than the giant cobblestone papillae that might have been expected.<sup>1</sup> There was no mucous discharge. This patient did not live in a warm, dry climate, but rather an urban U.S. environment.

Horner-Trantas dots need not be gelatinous to be considered in the diagnosis of VKC.<sup>10,17</sup> They are defined as degenerated eosinophils that deposit on the limbus,<sup>2</sup> and their appear-

ance can vary. Furthermore, VKC has several different classifications, and patients can be diagnosed with VKC whether or not they exhibit cobblestone papillae. The patient was therefore diagnosed with limbal VKC.

### **Potential Sequelae**

In addition to shield ulcers and punctate epithelial keratitis, recent literature suggests a possible association between VKC and the development of keratoconus, although no definitive causal relationship has been established.<sup>8-11</sup> This connection is more evident in subclinical keratoconus—corneal ectasia that is not yet visible on slit lamp examination but appears on slit scan topography such as the Orbscan (Bausch & Lomb Inc.).<sup>9,11</sup> A potential contributing factor to this association is the eye rubbing that these patients exhibit due to debilitating pruritis. In a prospective cross-sectional study by Gautam et al. in Kathmandu, Nepal, 26.8% of the patients studied with VKC also had keratoconus-like topography (KLT). All of the patients with KLT reported eye rubbing occasionally (five to ten times per day) or frequently (more than five times per day).<sup>10</sup>

### **Treatment**

The aforementioned sequelae illustrate the importance of early and effective treatment for VKC. In mild cases and for prophylaxis, a mast cell stabilizer is recommended 4-6 times per day. However, because of its slow onset of action, relief of symptoms may not be realized for up to two weeks.<sup>2</sup> Due to the initial appearance of the conjunctiva, this case was classified as mild. Treatment began with ketotifen to provide both the immediate relief from the antihistamine and the more long-term effects of the mast cell stabilizer. A mast cell stabilizer alone is preferred in more chronic treatment, as was implemented at later visits.

When the patient presents with moderate to severe corneal involvement, limbal infiltrates, giant papillae, or mucous discharge, a topical corticosteroid is indicated. A drug with low intraocular absorption is preferred in order to minimize the risk of IOP increase.<sup>2</sup> Due to insurance coverage and pediatric safety profiles, FML was the author's drug of choice, and IOP was monitored closely. Considering the moderate corneal involvement on initial presentation, initiating FML earlier in the course of treatment may have provided a faster resolution of signs and symptoms. In more severe cases, topical immunomodulators, systemic antihistamines or antileukotrienes, corticosteroid injections, and surgical corneal plaque removal can be considered.<sup>2</sup> Fortunately, this patient was treated before any more invasive measures became necessary.

When considering which medications to prescribe in the pediatric population, it is important to consider Food & Drug Administration (FDA) pediatric safety profiles. Appendices A and B illustrate the most recent FDA approvals for the various classes of anti-inflammatory and anti-allergic medications, respectively.

### **Conclusion**

While VKC may be mistaken as a simple allergic condition, it is essential that optometrists understand and recognize its potential complications when misdiagnosed or untreated. If the child in this case had not presented for a failed vision screening with the incidental finding of VKC, or if the diagnosis had been overlooked due to its uncommon presentation, it is possible that he may have developed further ocular sequelae. Whether pediatric patients present with or without classic allergic symptoms, it is crucial to examine the anterior segment thoroughly in order to diagnose atopic conjunctivitis as early as possible and treat effectively.

## References

1. Pattnaik L, Acharya L. A comprehensive review on vernal keratoconjunctivitis with emphasis on proteomics. *Life Sci* 2015;128:47–54. <http://bit.ly/2l6cdrz>
2. Leonardi A. Management of vernal keratoconjunctivitis. *Ophthalmol Ther* 2013;2:73-88. <http://bit.ly/2l5YFwb>
3. Hayilu D, Legesse K, Lakachew N, Asferaw M. Prevalence and associated factors of vernal keratoconjunctivitis among children in Gondar City, Northwest Ethiopia. *BMC Ophthalmol* 2016;16:167. <http://bit.ly/2kWDrrw>
4. Uchio E, Kimura R, Migita H, Kozawa M, et al. Demographic aspects of allergic ocular diseases and evaluation of new criteria for clinical assessment of ocular allergy. *Graefes Arch Clin Exp Ophthalmol* 2008;246:291-96. <http://bit.ly/2kWsLSZ>
5. Gerstenblith A, Rabinowitz M. Phlyctenulosis. In: *The Wills Eye Manual*, 6th Ed. Philadelphia: Lippincott Williams & Wilkins; 2012. <https://amzn.to/2l8JvpQ>
6. Gerstenblith A, Rabinowitz M. Acute Conjunctivitis. In: *The Wills Eye Manual*, 6th Ed. Philadelphia: Lippincott Williams & Wilkins; 2012. <https://amzn.to/2l8JvpQ>
7. Geraldini M, Chong Neto HJ, Riedi CA, Rosario N. Prevalence of allergic conjunctivitis in childhood. *World Allergy Organization J* 2012;132. <http://bit.ly/2mzp85C>
8. Al-Akily SA, Bamashmus MA. Ocular complications of severe vernal keratoconjunctivitis (VKC) in Yemen. *Saudi J Ophthalmol* 2011;25(3):291-4. <http://bit.ly/2muXOW2>
9. Taneja M, Ashar JN, Mathur A, Vaddavalli PK, et al. Measure of keratoconus progression in patients with vernal keratoconjunctivitis using scanning slit topography. *Contact Lens Anterior Eye* 2013;36(1):41-4. <http://bit.ly/2kXAIY3>
10. Gautam V, Chaudhary M, Sharma AK, Shrestha GS, et al. Topographic corneal changes in children with vernal keratoconjunctivitis: a report from Kathmandu, Nepal. *Contact Lens Anterior Eye* 2015;38(6):461-5. <http://bit.ly/2l7vGbo>
11. Totan Y, Hepsen IF, Cekic O, Gunduz A, et al. Incidence of keratoconus in subjects with vernal keratoconjunctivitis: A videokeratographic study. *Ophthalmol* 2001;108(4):824-7. <http://bit.ly/2kXE8dl>
12. Lee T, Yoo C, Hwang J, Lin S, et al. Comparison of intraocular pressure measurements between Icare Pro Rebound Tonometer and Tono-Pen XL Tonometer in supine and lateral decubitus body positions. *Curr Eye Res* 2015[cited 2018 Mar 21];40(9):923-9. <http://bit.ly/2kS3x82>
13. Chan W, Lloyd C, Symes RJ, Ashworth JL, et al. Accuracy of intraocular pressure measurement with the Icare Tonometer in children. *Asia-Pacific J Ophthalmol* 2015;4(6):357-9. <http://bit.ly/2mrVIMb>
14. Pflugfelder S. Considerations in atopic keratoconjunctivitis. *Johns Hopkins Adv Stud Ophthalmol* 2017;12(1):7-14.
15. Addis H, Jeng BH. Vernal keratoconjunctivitis. *Clin Ophthalmol* 2018;12:119-23. <http://bit.ly/2mbQxKV>
16. Malhotra C, Jain AK, Thapa B. Limbal pseudoepitheliomatous hyperplasia mimicking ocular surface squamous neoplasia in palpebral vernal keratoconjunctivitis. *Case Rep Ophthalmol Med* 2013[cited 2018 Nov 5], Available from: <http://dx.doi.org/10.1155/2013/527230>. <http://bit.ly/2mfpEp8>
17. La Rosa M, Lionetti E, Reibaldi M, Russo A, et al. Allergic conjunctivitis: A comprehensive review of the literature. *Italian J Ped* 2013[cited 2018 Nov 5];39(18). Available from: <https://ijponline.biomedcentral.com/track/pdf/10.1186/1824-7288-39-18>. <http://bit.ly/2kCdtCu>
18. Merriam Webster Online Dictionary[cited 2018 Nov 20]. Available from: <http://bit.ly/2kAtyIQ>.
19. Ferdi A, Kopsachilis N, Parmar D. Phlyctenulosis: A systemic diagnosis made or missed in the blink of an eye. *Clin Exp Optom* 2016;100(3):285-7. <http://bit.ly/2kCfZZs>

---

*Correspondence regarding this article should be emailed to Denise Alexopoulos, OD, at [dalexopoulos@ico.edu](mailto:dalexopoulos@ico.edu). All statements are the authors' personal opinions and may not reflect the opinions of the representative organization, OEPF, Optometry & Visual Performance, or any institution or organization with which the authors may be affiliated. Permission to use reprints of this article must be obtained from the editor. Copyright 2019 Optometric Extension Program Foundation. Online access is available at [www.oepf.org](http://www.oepf.org), and [www.ovpjournal.org](http://www.ovpjournal.org).*

Alexopoulos D, Vricella M. Limbal vernal keratoconjunctivitis: Prompt treatment can prevent visually threatening complications *Optom Vis Perf* 2019;7(4)213-21.

---



## Appendix A

### Anti-Inflammatory Medications Used in Pediatric Allergic Eye Disease: Indication, Age Approval, and Dosing

CATEGORY	NAME	BRAND NAME	INDICATION	APPROVED AGE	APPROVED DOSING
NSAID	ketorolac 0.5% solution	Acular	Seasonal allergic conjunctivitis	2 years	1 drop qid
Steroid	fluorometholone acetate 0.1%/0.25% suspension	FML Liquifilm, Fluor-Op, Flarex, FML Forte Liquifilm	Steroid-responsive inflammatory conditions	2 years	1 drop bid-qid For 1st 24-48 hrs: can increase to 2 drops q2hrs
	fluorometholone acetate 0.1%/0.25% ointment	FML S.O.P, FML Forte S.O.P.	Steroid-responsive inflammatory conditions	2 years	1.5" in ribbon qd-tid For 1st 24-48 hrs: can increase to 1 application q4hrs

## Appendix B

### Anti-Allergic Medications for Children: Indication, Age Approval, and Dosing

ANTI-ALLERGIC CATEGORY	NAME	BRAND NAME(S)	INDICATION	APPROVED AGE	APPROVED DOSING
Antihistamine	alcaftadine 0.25% solution	Lastacaft	Allergic conjunctivitis	2 years	qd
	azelastine 0.05% solution	Optivar	Allergic conjunctivitis	3 years	bid
	bepotastine 1.5% solution	Bepreve	Allergic conjunctivitis	2 years	bid
	cetirizine	Zerviate	Allergic conjunctivitis	2 years	bid
	emedastine 0.05% solution	Emadine	Allergic conjunctivitis	3 years	up to qid
	epinastine 0.05% solution	Elestat	Allergic conjunctivitis	2 years	bid
Mast cell stabilizer	cromolyn 4.0% solution	Crolom	Allergic conjunctivitis, vernal keratoconjunctivitis, vernal keratitis	4 years	1-2 drops 4-6x/day
	lodoxamide 0.1% solution	Alomide	Allergic conjunctivitis, vernal keratoconjunctivitis, vernal keratitis	2 years	1-2 drops qid for up to 3 months
	nedocromil 2.0% solution	Alocril	Allergic conjunctivitis	3 years	1-2 drops bid
	pemirolast 0.1% solution	Alamast	Allergic conjunctivitis	3 years	1-2 drops qid
Combinations (MCS & H1 antagonist)	ketotifen 0.025%	Alaway, Claritin Eye, TheraTears Allergy, Zaditor, Zyrtec Itchy Eye Drops	Allergic conjunctivitis	3 years	bid
	olopatadine 0.2% solution	Pataday	Allergic conjunctivitis	2 years	qd
	olopatadine 0.1% solution	Patanol	Allergic conjunctivitis	3 years	bid
	olopatadine 0.7% solution	Pazeo	Allergic conjunctivitis	2 years	qd