

# Article ▶ Conversion Disorder Presenting with Unilateral Photophobia and Vision Loss

Amy Chang, OD, Minneapolis, Minnesota

Jennifer Bateman, OD, Womack Army Medical Center, Fort Bragg, North Carolina

José E. Capó-Aponte, OD, PhD, Womack Army Medical Center, Fort Bragg, North Carolina

## ABSTRACT

**Background:** Conversion disorder is a rare condition and consequently is often misdiagnosed. Patients suffer from neurological symptoms in the absence of an organic cause. Symptoms arise in response to a stressful or traumatic situation affecting the patient's mental health which converts to a physical problem. Although it is a psychiatric condition, conversion disorder typically affects motor or sensory systems.

**Case Report:** This report describes a 38-year-old military female presenting with unilateral photophobia and vision loss resulting from a traumatic combat experience. The diagnosis of conversion disorder was made after ruling out organic causes (e.g., ocular, visual, neurological) and extensive history and health record review.

**Conclusion:** Conversion disorder should be considered in patients with a sensory visual deficit in the absence of an organic cause. A thorough review of the patient's psychological history is important when dealing with unexplained sensory deficits.

**Keywords:** conversion disorder, functional vision loss, malingering, mild traumatic brain injury, photophobia

## Introduction

Patients presenting with a sensory visual deficit in the absence of an apparent organic cause pose a diagnostic dilemma, often raising suspicions of malingering. Eye care providers must consider the possibility of less common conditions, such as conversion disorder, when encountering such challenges. Conversion disorder was originally known as hysteria during the 19th century.<sup>1</sup> It is a condition where a patient suffers from neurological symptoms in the absence of pathology. These symptoms commonly arise in response to stressful or traumatic situations affecting the patient's mental health which converts to a physical problem, leading to the name of conversion. Conversion disorder is considered a psychiatric condition typically affecting the motor or sensory system<sup>2</sup> with a prevalence rate of 0.5-1.0% (Table 1).<sup>3</sup>

As the causative event leading to conversion disorder may also result in traumatic brain injury (TBI), the effects of TBI on the visual system are relevant to the diagnosis of conversion disorder. The vast majority of TBIs are concussions, also termed mild TBI (mTBI), which have been described as the most common neurological event in civilians<sup>4</sup> and US military personnel returning from combat.<sup>5-9</sup> Mild TBI is generally defined as an insult to the brain caused by an external physical force with normal imaging (e.g., computed tomography (CT) or magnetic resonance imaging (MRI)), altered or loss of consciousness for less than 30 minutes, and post-traumatic amnesia for less than 24 hours. Ocular-motor dysfunctions (i.e., vergence, version, accommodation) and photophobia are the most common visual deficits associated with mTBI.<sup>6-12</sup> Fortunately, in the majority of individuals, mTBI symptoms

**Table 1: Diagnostic Criteria for Conversion Disorder<sup>2</sup>**

1	Having at least one motor or sensory deficit suggestive of a neurological or general medical condition
2	Symptoms are preceded by a traumatic or stressful event
3	Patient is not malingering
4	Symptoms cannot be explained by a general medical condition or drug use
5	Symptoms cause clinically significant distress and affect social or occupational activities
6	Symptoms are not limited to pain or sexual problems and cannot be explained by another mental disorder

resolve within three months of injury.<sup>13,14</sup> The prevalence of persistent symptoms varies from 7-33%.<sup>15-17</sup> However, a commonly accepted estimate of the patients with persistent symptoms is currently 20%. Optometrists must remain cognizant that a small number of mTBI patients, those whose symptoms do not resolve in the three month window, may be the ones who present for an eye examination. This group of mTBI patients with persistent deficits will require ongoing medical care to manage their symptoms. Understanding mTBI visual sequelae will aid providers in differentiating true mTBI visual symptoms versus conversion disorder. The following report presents a case of undiagnosed conversion disorder that progressed to a deeply embedded functional unilateral vision loss and debilitating photophobia.

## Case Report

A 38-year-old white female US Army trauma nurse reported to the Womack Army Medical Center (WAMC) for a

**Table 2: Pertinent Examination Findings**

Examination	OD	OS
Distance Snellen Acuity (cc)	20/40 <sup>+2</sup>	20/20
Near Snellen Acuity (sc)	20/160	20/20
Refraction	-3.00-1.00/85	-3.25-0.75/85
Cover Test, Distance and Near	Orthophoric	
<b>Accommodative Amplitude</b>		
Minus Lens Method	Not performed due to poor near acuity	5.25 diopters
Monocular Estimation Method	+0.25-0.50x090	Not performed
Extraocular Motility	Full range of motion	Full range of motion
Pupils	Equal, round, reactive; no afferent defect	
Ocular Adnexa	Healthy lids/lashes	
Conjunctiva and Sclera	Free from injection	
Cornea	Clear with healthy tear film	
Anterior Chamber	Deep and quiet	
Iris	Brown, flat, & intact	
Lens	Clear from media opacities	
Vitreous	Clear	
Optic Nerve	C/D 0.25 round, pink and distinct borders	
Retinal Vessels	Normal, artery to vein ratio 2/3	
Macula	Flat, intact, & clear	
Background Fundus	Free from breaks or defects	
Peripheral Retina	Free from breaks or defects	

neuro-optometric evaluation with a complaint of photophobia in her right eye and blurred vision. She elaborated that the right eye vision was similar to what is experienced while looking through a kaleidoscope, and she had to work hard to focus with that eye. She reported no changes in her eyes or vision since her last examination two months prior. The patient was wearing a black pupil prosthetic contact lens (Alden Optical, Lancaster, NY) in the right eye which was prescribed by her previous eye care provider. Her medical history was positive for hypothyroidism secondary to a left hemi-thyroidectomy procedure for thyroid cancer, insomnia, generalized anxiety, and premature ovarian insufficiency. These diagnoses were made years prior to her military deployment. Her post-deployment medical history included low frequency hearing loss on the right side, conductive hearing loss, adjustment disorder with anxiety, post-traumatic stress disorder, post-traumatic insomnia resulting from combat exposure, and concussion. Her medications were levothyroxine, fexofenadine, triazolam, bupropion, clonazepam, diazepam, citalopram, and temazepam.

A comprehensive ophthalmological and neuro-optometric evaluation was performed (Table 2). Differential diagnosis for monocular vision loss and photophobia is in Table 3. Given a lack of ocular pathology to account for her monocular visual

**Table 3: Differential Diagnosis for Unilateral Vision Loss and Photophobia**

Condition	Unilateral vision loss	Unilateral photophobia	Other features
Amblyopia	Yes	No	Longstanding decreased visual acuity secondary to uncorrected anisometropia or constant strabismus
<b>Anterior Segment</b>			
Dry Eye	No	No	Positive staining with fluorescein, decreased tear break up time
Central Corneal Opacity	Yes	No	Positive finding on biomicroscopy
Keratitis	Yes	No or bilateral	Positive finding on biomicroscopy
Uveitis	Yes	No	Cells and/or flare in anterior chamber
<b>Posterior Segment</b>			
Cataract	Yes	Yes	Positive finding on biomicroscopy
Vitritis	Yes	Yes	Positive finding on biomicroscopy
Macular Disease	Yes	Yes	Positive finding on ophthalmoscopy
Retinitis Pigmentosa	No	No	Positive finding on ophthalmoscopy
Optic Neuritis/ Optic Atrophy	Yes	No	Positive finding on ophthalmoscopy Decreased vision only on end stage
Glaucoma	No	No	Positive finding on ophthalmoscopy
Migraine	No	No	Migraine is usually a transient positive phenomenon, bilateral photophobia
Mild Traumatic Brain Injury (mTBI)	No	No	mTBI does not result in decreased distance visual acuity. Patients do often complain of photophobia, but it is bilateral
Accommodative Spasm	Yes	No	Associated with fluctuating Monocular Estimation Method and pupillary miosis

loss and photophobia, a comprehensive record review was performed.

### Comprehensive Electronic Health Record Review and Past History

**Year 1.5 Pre-Trauma:** The patient had a routine eye examination documented on her electronic health record (EHR) with a diagnosis of compound myopic astigmatism in each eye. The refraction was -3.00-0.75x086 and -3.00

-0.75x085 in the right and left eyes, respectively, with a best-corrected distance acuity of 20/20<sup>+</sup> and normal ocular health in both eyes.

**Trauma:** The patient's vision problems were noted after her combat experience in Iraq, 28 months prior to her visit to the WAMC Neuro-Optometry Clinic. She was exposed to rocket propelled grenade rounds for 10 minutes, where she was thrown to the ground with impact on the left side of her head. Unsure whether she lost consciousness, she reported no post-traumatic amnesia. She reported that her 'battle buddy' fell on her during the event and subsequently lost both arms to amputation, and another Soldier in close proximity was killed. She reported having a severe headache, feeling overheated, nausea, and difficulty focusing for a number of days after the trauma.

**Month 3 Post-Trauma:** Upon returning from her deployment, she had a routine eye examination with no complaints. Evaluation led to a diagnosis of compound myopic astigmatism in each eye. The refraction was -3.00-0.75x086 and -3.00-0.50x070 for the right and left eyes, respectively, with best-corrected distance acuity of 20/20 OD, OS and normal ocular health OU. Soon after, she was evaluated by neurology and diagnosed with combat-related adjustment disorder with anxiety, post-traumatic stress disorder, post-traumatic insomnia, and concussion. MRI and CT imaging were normal and negative for brain injury.

**Month 7 Post-Trauma:** She presented for eye care with a complaint of difficulty focusing with the right eye, and reported that the right eye wandered when watching television. Her refraction was unchanged from the recent examination; her acuities measured 20/20 in each eye, although the provider noted that it was "slow" in the right eye. An esophoria of 4 diopters at distance and 8 at near with reduced near vergence ranges of base in x/4/2 and base out x/6/0 were recorded. She was diagnosed with esophoria and prescribed a +1.25 add for near work with a recommendation of pencil push-ups for home vision therapy. She was also diagnosed with a disorder of accommodation with notation that the patient might be experiencing an early form of Adie's pupil due to parasympathetic damage on the right side. However, there was no notation of objective clinical findings to support that diagnosis. Ocular health was reported as normal in both eyes.

**Month 10 Post-Trauma:** The patient was seen at a neuro-ophthalmology clinic, where she reported that the right eye had been blurred since the event and had not changed. She reported severe photosensitivity and indirect sunlight causing severe headaches and nausea. Her visual acuity in the right eye was 20/40<sup>-2</sup> with her current spectacles. The diagnosis was diplopia with variable large-angle esotropia, most consistent with accommodative spasm and possible traumatic optic neuropathy in the right eye. She was also diagnosed with light sensitivity without ocular etiology, and sunglasses were recommended. The same month, she reported to an ophthalmology clinic with decreased vision in the right eye

for 6 days, floaters for 6 days, and eye twitching. Her best-corrected visual acuities were 20/100 and 20/20 in the right and left eyes, respectively. The ocular health examination was normal, and the provider noted that no floaters were seen.

**Month 12 Post-Trauma:** She was fitted bilaterally with tinted contact lenses at a Veterans Administration (VA) hospital that provided relief from asthenopia due to fluorescent lighting. Unfortunately, there was no additional information documented regarding the type of lens or tint. Her visual acuity was 20/30<sup>-2</sup> in the right eye and 20/20 in the left eye, but ocular health assessment was not performed. Transition lenses were also prescribed, and a recommendation was given to purchase yellow filter lenses for driving.

**Month 15 Post-Trauma:** The patient presented for a new contact lens fit for the right eye for light sensitivity and difficulty focusing. Visual acuities were 20/400 best corrected for the right eye and 20/20 for the left. The anterior segment evaluation was normal. The patient was dispensed a soft contact lens from Alden Optical with a 6 mm black pupil with a clear periphery. Four follow-up visits for contact lens or refitting were documented; however, visual acuity was not recorded for the first three visits for her right eye and recorded as light perception for the last encounter. The acuity for the left eye ranged from 20/20 to 20/30 during these encounters.

**Month 24 Post-Trauma:** The patient was re-evaluated by an ophthalmologist for a military Medical Evaluation Board. A diagnosis was made of right optic nerve injury with documentation that the service member was "legally blind" in the right eye per the neuro-ophthalmology report and annotation that ocular health was normal.

After the comprehensive interview and electronic health record review, she was diagnosed with light sensitivity and conversion disorder. This diagnosis will be explained in the discussion. The diagnosis was discussed with the patient, and a recommendation was made for the patient slowly to taper off wearing the occlusion contact lens and to continue to follow up with psychology and psychiatry. Unfortunately, the patient was discharged from the military before any treatment was provided.

## Discussion

This case was complex on presentation, as a thorough ocular and neuro-optometric evaluation was necessary as well as review of her past health records with eye care providers, neurologists, and behavioral health specialists. Besides consideration of conversion disorder, malingering and exaggerating are diagnoses of exclusion that must be considered. Malingering is defined as intentionally counterfeiting a disease with benefit instinct. Benefit may be monetary or nonmonetary. This is different than exaggerating, which is misattributing symptoms to an irrelevant clinical entity. The goal of the patient may include escape from military service or work, reduction of court penalty, compensation from government agencies or insurance companies, and acquiring medication or

medical equipment. The aim is rarely attraction of sympathy. Malingering is often distinguishable from conversion disorder as patients seriously challenge if told they are malingering or over-exaggerating. They may become furious and even assault the physician and express anger with long evaluations.<sup>18</sup> This is in contrast to a patient with conversion disorder who usually sincerely cooperates during the examination. The patient is often calm and surprisingly indifferent to his/her grave complaints. After exam completion, when educated that their eyes are healthy and that there is nothing consistent with their complaints on evaluation, the patient will admit diagnosis easily and be thankful to the provider. This is assuming the patient has not been treated for the symptoms previously or been misdiagnosed.

In the above case, the patient presented for a neuro-optometry evaluation after being treated for her right eye complaints for over a year, the most extreme being with the contact lens patch. This long-term sensory deprivation of her eye, the medical validation of her symptoms, and the misdiagnosis caused her to have a negative reaction when educated that there was no organic basis for her ocular complaints. Here, the detriment of delayed diagnosis and prolonged mistreatment was evident. This patient did not experience binocular stereopsis and had reduced visual fields because of the occlusion contact lens in her right eye.

The patient's examination and history review were consistent with the diagnostic criteria for conversion disorder.<sup>2</sup> The patient discussed here: 1) had sensory deficits suggestive of a neurological condition (i.e., unilateral vision loss and photophobia); 2) had symptoms that were preceded by a traumatic combat event; 3) was not malingering since she continuously sought eye care to mitigate her visual symptoms; 4) had symptoms that could not be explained by a general medical condition or drug use; 5) had symptoms that caused clinically significant distress such that she continued to seek treatment to alleviate monocular photophobia; and 6) had symptoms that could not be explained by another mental disorder.

There are different theories about the cause of conversion disorder. It can be broadly understood as the result of an interaction among conflicts within the internal psychological processes of the individual which incorporates their beliefs about illness and learned maladaptive behavior.<sup>19</sup> There is little research aimed at understanding the prognosis for those with conversion disorder, but results from a few recent studies suggest that the chance for immediate recovery is good, though relapse is common. Acute onset and prompt treatment are factors that are associated with quick recovery.<sup>20</sup> A longitudinal study showed that 43% of males and 35% of females were symptomatic at one year, which reduced to 25% and 22%, respectively, at five years and changed minimally at 15 years.<sup>21</sup> A more recent study has found that the rate of misdiagnosis of conversion disorder has been high in the past, but more recently, since 1970, the prevalence is consistently at 4%. This study also

described that the most commonly missed symptoms related to conversion disorder were gait and movement disorders.<sup>22</sup> Based on recent adult population studies, conversion disorder should not be a diagnosis of exclusion, since early identification can ensure prompt treatment and improve outcomes.<sup>23</sup> Unfortunately, the literature mainly consists of case studies with no systematic reviews of patients who received intervention. Treatment options include psychosocial interventions,<sup>24</sup> cognitive-behavioral therapy,<sup>25,26</sup> hypnosis, and long term analytical psychotherapy.<sup>27</sup>

When ruling out organic diagnoses for these symptoms in patients with trauma, it is important to remember that the prevalence of traumatic optic neuropathy is low; between 0.5-5% of all closed head trauma. Traumatic optic neuropathy is defined as traumatic vision loss that can occur without ophthalmic evidence of injury. However, a relative afferent pupillary defect (RAPD) will be present, and the vision loss is always present acutely. This patient had no evidence of an RAPD and had documented 20/20 visual acuity up to 7 months after the date of the traumatic event. This patient also reported severe photophobia, mainly in her right eye.

Since conversion disorder can result from a traumatic event, eye care providers must take into consideration that photophobia is a common symptom in patients with persistent post-concussion syndrome.<sup>28</sup> There have been multiple retrospective studies in the VA hospitals and military treatment facilities documenting the prevalence of photosensitivity to be approximately 50%.<sup>6,7,29</sup> The term photophobia is a misnomer as it is defined as an abnormal sensitivity to light. When the eye is exposed to light, discomfort is experienced in the eye or head, and this may also cause an avoidance reaction without overt pain. Photo-oculodynia can be used to describe light-induced eye pain from a normally non-painful source (e.g., ambient lighting).<sup>30</sup> While photosensitivity in mTBI patients is normally thought of as light sensitivity outdoors, there are a smaller number of individuals who have photo-oculodynia with light sensitivity indoors, usually from fluorescent lighting.<sup>31</sup>

Two distinct pathways mediate photophobia. The first pathway points out that the retina does not have pain receptors, but the optic nerve does contain pain-sensing neurons within blood vessels.<sup>30</sup> In this circuit, the light stimulates ganglion cells that project light-related signaling to the midbrain, which causes ocular vasodilation and activation of pain-sensing neurons on blood vessels. These afferent neurons then project onto the thalamus and cortex, where pain is perceived. The second pathway is more direct and was identified by Nosedá,<sup>32</sup> in which intrinsically photosensitive retinal ganglion cells (IPRGCs) project directly to thalamic neurons that are associated with somatosensation and pain. Because these thalamic neurons respond to painful stimulation of the dura as well as light, these neurons are positioned to interpret light as a nociceptive signal. In a sense, these can be considered "photophobia neurons." From the thalamus, this information is projected into the cortex in a pattern that



**Figure 1:** FL-41 tint with 55% optical density. Source: Axonoptics.com



**Figure 2:** Blue tint with 20% optical density



**Figure 3:** Gray tint with 40% optical density (base) that transitions to 80% optical density.

suggests a broadly distributed, multisensory and nociceptive response for photophobia.

Photophobia resulting from mTBI is usually bilateral. Therefore, it is important to be cautious with patients who report unilateral or asymmetric photophobia. If no examination findings support the photophobia complaint, such as asymmetric media opacity, retinal disease, or optic neuropathy, unilateral photophobia of an organic nature can be ruled out. There exist no cortical processes explaining unilateral photophobia. A thorough literature search does not yield case studies on patients with unilateral photosensitivity (all obviously in the setting of normal ocular health). A review of 2000 patients with a history of TBI seen at WAMC from 2011 to 2013 produced two cases of unilateral photosensitivity, both of which had concurrent non-organic visual loss. Considering the pathways for photophobia, our patient's complaint of unilateral photophobia is inconsistent. The patient was experiencing conversion disorder, where she was transferring her psychological illness into sensory symptoms. Early intervention with these patients is critical so that focus can turn to the treatment of their underlying psychiatric disorder.

If no clear diagnosis exists for monocular decreased vision loss and photophobia, milder treatment of the photophobia is significantly preferable to implementing an occlusion lens. In patients like the one discussed here, this therapy can also be considered to transition her out of her occlusion contact lens. In cases of photophobia, a recommendation of sunglasses with specific tint is helpful. The published reports on tint use have limitations, and larger scale studies are necessary to increase confidence prior to prescribing them. However, clinical experience may be usefully employed when prescribing. Some studies have shown a benefit to red- or pink-tinted lenses in decreasing symptoms,<sup>33,34</sup> while other research shows blue or short wavelength blocking lenses to induce photophobia.<sup>35</sup>

These studies employed the FL-41 lens with 55% optical density (Figure 1). These separate studies were done on school-age children with migraines and patients with benign essential blepharospasm.

In the WAMC Neuro-Optometry Clinic, blue tint at 15-20% optical density (Figure 2) has been repeatedly useful in patients with photo-oculodynia, or sensitivity to ambient lighting. The clinical experience at WAMC is consistent with Digre's<sup>30</sup> that chronic darkness will increase the perception and pain of light sensitivity, and therefore dark tinted lenses are not recommended to these patients. A light blue tint has anecdotally shown to decrease photophobia and discomfort indoors in a significant group of patients, especially with computer screens and in rooms with fluorescent lighting. A few large studies have shown that blue-tinted lenses suppress the photo paroxysmal response, which is a type of epilepsy.<sup>36,37</sup> Lenses which change percentage of tint gradually depending upon illumination (i.e., transition lenses) may also be recommended for patients who frequently travel between indoors and outdoors. Transition lenses with a base tint of approximately 30-40% indoors receive the most positive feedback in the group of active patients with symptoms of photo-oculodynia at the WAMC Neuro-Optometry Clinic (Figure 3).

Unfortunately, much of the optical treatment of photophobia is still anecdotal. As our understanding of photophobia and treatment is still lacking, in-office individualized patient testing is recommended. A "tint kit" including several tint options such as gray, amber, blue, and FL-41 at low optic density levels is invaluable. Without consistent and large scale research, providing symptomatic patients in-office with different tint options is the best clinical practice.

Conversion disorder is a relatively stable psychiatric diagnosis and is not expected to change with time. No disease explanation is subsequently identified.<sup>34</sup> It is common for patients to be discharged back to their general practitioners in the hope that the symptoms will diminish; however, the evidence from longitudinal studies suggests that the majority of patients will continue to report physical symptoms and associated disability.<sup>38</sup> When evaluating subjective patient complaints, it is imperative to rely on objective tests. If thorough objective testing is not possible, in the case of severe photophobia, the provider should familiarize him- or herself with current research. Attributing symptoms to larger diagnoses

uch as TBI can be avoided with a careful understanding of the mechanism of brain injury. The most common form of brain injury, mTBI, rarely leads to vision loss. A careful review of the patient's medical history is helpful in uncovering inconsistencies in reporting that make the analysis and diagnosis of conversion disorder easier.

## Conclusion

This paper reviews an unfortunate case of undiagnosed conversion disorder which resulted in iatrogenic functional unilateral blindness. Although patients with conversion disorder are more traditionally seen in primary or acute-care settings with symptoms of pain or fatigue, they can present to optometric professionals as well. It is essential for eye care providers to have a basic understanding of this psychiatric disorder, as it can manifest with visual symptoms that are inconsistent with objective findings. The difficult diagnosis of conversion disorder can be further complicated by patients who have experienced a traumatic event, such as a TBI, and/or who suffer from concurrent neurologic disease. Although most vision care providers are not extensively trained in neurology, an understanding of visual symptoms that are consistent with neuro-ophthalmological disease is imperative. It may be tempting to charge the unexplained visual symptoms to the neurologic event or disease, but this can be severely detrimental to the patient's recovery. Optical occlusion in this case provided validation for the patient's conversion visual symptoms. If there is a delay in treatment or referral, there is a greater chance that they will not fully recover. Thorough questioning of the patient's psychiatric history and review of their health records may provide insight into their psychiatric health. If records are unavailable, or if the patient has not been evaluated by a behavioral health provider, then a referral is prudent.

## References

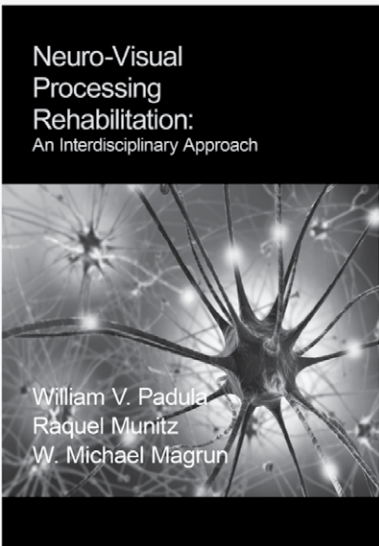
- Breuer J, Freud S. *Studies On Hysteria*. New York: Basic Books, 1895. Available on line at: <http://bit.ly/1P6eJFE>. Last Accessed October 18, 2013.
- Association AP. *Diagnostic and Statistical Manual of Mental Disorders, Fifth Edition*. Arlington: American Psychiatric Publishing, 2013. Available on-line at <http://bit.ly/1jwaj3T>. Last Accessed October 18, 2013.
- Bhui K, Hotopf M. Somatization disorder. *British J Hosp Med* 1997;58:145-9.
- CDC. *Injury Prevention & Control: Traumatic Brain Injury*. Center for Disease Control and Prevention. 2013; Available from: <http://bit.ly/CDC-TBI>. Last Accessed October 18, 2013.
- DoD. *DoD Numbers for Traumatic Brain Injury*. 2012 [August 16, 2013]; Available from: <http://1.usa.gov/1GTHNX5>. Last Accessed October 18, 2013.
- Capo-Aponte JE, Urosevich TG, Temme LA, Tarbett AK, Sanghera NK. Visual dysfunctions and symptoms during the subacute stage of blast-induced mild traumatic brain injury. *Mil Med* 2012;177:804-13.
- Goodrich GL, Kirby J, Cockerham G, Ingalla SP, Lew HL. Visual function in patients of a polytrauma rehabilitation center: A descriptive study. *J Rehab Res Devel* 2007;44:929-36.
- Okie S. Traumatic brain injury in the war zone. *N Engl J Med* 2005;352:2043-7.
- Stelmack JA, Frith T, Van Koeveing D, Rinne S, Stelmack TR. Visual function in patients followed at a Veterans Affairs polytrauma network site: an electronic medical record review. *Optometry* 2009;80:419-24.
- Ciuffreda KJ, Kapoor N, Rutner D, Suchoff IB, et al. Occurrence of oculomotor dysfunctions in acquired brain injury: a retrospective analysis. *Optometry* 2007;78:155-61.
- Dougherty AL, MacGregor AJ, Han PP, Heltemes KJ, Galarneau MR. Visual dysfunction following blast-related traumatic brain injury from the battlefield. *Brain Inj* 2011;25:8-13.
- Kapoor N, Ciuffreda KJ. Vision disturbances following traumatic brain injury. *Curr Treat Options Neurol* 2002;4:271-80.
- Fee CR, Rutherford WH. A study of the effect of legal settlement on post-concussion symptoms. *Archives of emergency medicine* 1988;5:12-7.
- Levin HS, Mattis S, Ruff RM, Eisenberg HM, et al. Neurobehavioral outcome following minor head injury: a three-center study. *Journal of neurosurgery* 1987;66(2):234-43.
- Binder LM, Rohling ML, Larrabee GJ. A review of mild head trauma. Part I: Meta-analytic review of neuropsychological studies. *J Clin Exp Neuropsychol* 1997;19:421-31.
- Alexander MP. Mild traumatic brain injury: Pathophysiology, natural history, and clinical management. *Neurology* 1995;45:1253-60.
- Rimel RW, Giordani B, Barth JT, Boll TJ, Jane JA. Disability caused by minor head injury. *Neurosurgery* 1981;9:221-8.
- Incesu AI, Sobaci G. Malingering or simulation in ophthalmology-visual acuity. *Int Ophthalmol* 2011;4(5):558-66.
- Silver FW. Management of conversion disorder. *Am J Phys Med Rehab* 1996;75:134-40.
- Ron M. The Prognosis of Hysteria/somatization Disorder. In: Halligan P, Bass C, Marshall JC, eds. *Contemporary Approaches to the Study of Hysteria*. Oxford: Oxford University Press, 2001.
- Ljungberg L. Hysteria: A clinical, prognostic and genetic study. *Acta psychiatrica et neurologica Scandinavica Supplementum* 1957;112:1-162.
- Stone J, Smyth R, Carson A, Lewis S, et al. Systematic review of misdiagnosis of conversion symptoms and "hysteria." *BMJ* 2005;331(7523):989.
- Krasnik C, Grant C. Conversion disorder: Not a malingering matter. *Paediatrics Child Health* 2012;17:246.
- Duckworth K, Freedman J. *Psychosocial Treatments*. National Alliance on Mental Illness 2012; Available from: <http://bit.ly/1K1RUWc>. Last Accessed October 18, 2013.
- Duckworth K, Freedman J. *Cognitive Behavioral Therapy (CBT)?* National Alliance on Mental Illness 2012; Available from: <http://bit.ly/1IVUVQo>. Last Accessed October 18, 2013.
- Kroenke K, Swindle R. Cognitive-behavioral therapy for somatization and symptom syndromes: a critical review of controlled clinical trials. *Psychother Psychosom* 2000;69(4):205-15.
- Buhler KE, Heim G. Etiology, pathogenesis, and therapy according to Pierre Janet concerning conversion disorders and dissociative disorders. *Am J Psychother* 2011;65:281-309.
- Bohnen N, Twijnstra A, Wijnen G, Jolles J. Tolerance for light and sound of patients with persistent post-concussional symptoms 6 months after mild head injury. *J Neurol* 1991;238:443-6.
- Bulson R, Jun W, Hayes J. Visual symptomatology and referral patterns for Operation Iraqi Freedom and Operation Enduring Freedom veterans with traumatic brain injury. *J Rehab Res Devel* 2012;49(7):1075-82.
- Digre KB, Brennan KC. Shedding light on photophobia. *J Neuro-ophthalmol* 2012;32:68-81.
- Fine PG, Digre KB. A controlled trial of regional sympathectomy in the treatment of photo-oculodinia syndrome. *J Neuro-ophthalmol* 1995;15:90-4.
- Nosedá R, Constandil L, Bourgeois L, Chalus M, Villanueva L. Changes of meningeal excitability mediated by corticotrigeminal networks: a link for the endogenous modulation of migraine pain. *J Neurosci* 2010;30:14420-9.
- Blackburn MK, Lamb RD, Digre KB, Smith AG, et al. FL-41 tint improves blink frequency, light sensitivity, and functional limitations in patients with benign essential blepharospasm. *Ophthalmology* 2009;116:997-1001.

34. Carson AJ, Best S, Postma K, Stone J, et al. The outcome of neurology outpatients with medically unexplained symptoms: a prospective cohort study. *J Neurol Neurosurg Psychiatry* 2003;74:897-900.
35. Main A, Vlachonikolis I, Dowson A. The wavelength of light causing photophobia in migraine and tension-type headache between attacks. *Headache* 2000;40:194-9.
36. Capovilla G, Gambardella A, Rubboli G, Beccaria F, et al. Suppressive efficacy by a commercially available blue lens on PPR in 610 photosensitive epilepsy patients. *Epilepsia* 2006;47:529-33.
37. Kepecs MR, Boro A, Haut S, Kepecs G, Moshe SL. A novel nonpharmacologic treatment for photosensitive epilepsy: a report of three patients tested with blue cross-polarized glasses. *Epilepsia* 2004;45:1158-62.
38. Wessely S, Chalder T, Hirsch S, Wallace P, Wright D. The prevalence and morbidity of chronic fatigue and chronic fatigue syndrome: a prospective primary care study. *Am J Pub Health* 1997;87:1449-55.

Correspondence regarding this article should be emailed to Amy Chang, OD, at [achang05@gmail.com](mailto:achang05@gmail.com). All statements are the authors' personal opinions and may not reflect the opinions of the representative organizations, ACBO or OEPE, Optometry & Visual Performance, or any institution or organization with which the authors may be affiliated. Permission to use reprints of this article must be obtained from the editor. Copyright 2015 Optometric Extension Program Foundation. Online access is available at [www.acbo.org.au](http://www.acbo.org.au), [www.oepf.org](http://www.oepf.org), and [www.ovpjournal.org](http://www.ovpjournal.org).

Chang A, Bateman J, Capó-Aponte JE. Conversion disorder presenting with unilateral photophobia and vision loss. *Optom Vis Perf* 2015;3(3):151-7.

***The online version of this article contains digital enhancements.***



\*\*OEP Clinical Associates receive this publication in softcover as an enrollment benefit publication\*\*


## Neuro-Visual Processing Rehabilitation: An Interdisciplinary Approach

*By William V. Padula, Raquel Munitz and W. Michael Magrun*

Understanding how we see brings to mind the mythical story of the blind men and the elephant. Each responded to the part of the elephant that he encountered, and thus each had a very different impression of the animal. We are often so preoccupied with our conscious visual world that we describe it in limited ways and are thus unable to understand the comprehensive nature of vision. Research has shown that there is much more to visual processing than we have recognized. However, our limited understanding of vision and its multiple sensorimotor interactions have restricted our ability to work, through vision, to affect the rehabilitation of those who are neurologically challenged. The authors invite you to explore *Neuro-Visual Processing Rehabilitation* to learn new ways to think about vision. This book delves into the visual processing relationships of child development, motor and sensory interactions, and postural organization, led by vision, as the basis for understanding vision. From this knowledge, new directions and options will emerge for rehabilitation through the use of non-compensatory prisms and a new mode of treatment that the authors have termed Neuro-Visual Postural Therapy. The implications of understanding neuro-visual processing will change your thinking about vision as well as provide possibilities for helping millions of children and adults who have a neurological condition. Hardbound, 236 pages.

**#OEPNVPR-H      \$79.95 plus s/h**

To place your order:  
 Phone 800.424.8070      •      Online at [www.oepf.org](http://www.oepf.org)  
 OEP Foundation, Inc, 1921 E Carnegie Ave, Suite 3L, Santa Ana, CA 92705



OPTOMETRIC  
EXTENSION  
PROGRAM  
FOUNDATION