

Article ▶ Benign or Malign? A Syndrome of Acquired Hyperopia with Choroidal Folds

Michael Au, OD, Nova Southeastern University, Davie, Florida

ABSTRACT

Background: Acquired hyperopia with choroidal folds is a benign syndrome characterized by flattening of the posterior pole in the affected eye, enlargement of the optic nerve complex, and the presence of a perineural space. The mechanisms responsible for these findings remain unclear, although choroidal folds have a number of possible etiologies, ranging from benign causes to malignant intraorbital masses. The proper workup is therefore critical to determine and to manage underlying pathologies. This case report presents a patient workup and management with unilateral acquired hyperopia and choroidal folds.

Case Summary: A 26-year-old female presented with intermittent diplopia of increasing frequency in January 2013. In 2011, she was diagnosed with convergence insufficiency and unexplained partial hearing loss. A family history of hearing loss secondary to tumor growth prompted recommendations of yearly MRI studies. Upon refraction, retinoscopy yielded a hyperopic shift of +2.00D in the left eye compared to an examination two years prior. Fundus examination showed subtle radiations extending temporally from the optic nerve and concentrically from the macula. An OCT study revealed slight elevation nasal to the macula, with folds seen in the retinal layers. A referral was made for neuro-ophthalmic evaluation to rule out the presence of a mass. The patient received an MRI and was diagnosed with a benign syndrome of hyperopia with choroidal folds.

Conclusion: Although choroidal folds can appear in the company of benign and idiopathic causes, this case report illustrates the need for thorough workup to rule out underlying pathology, as they can be potentially ominous. Moreover, it is also necessary to differentiate between functional and organic causes of diplopia before considering treatment with prism or vision therapy. Having been cleared of pathology, the patient was enrolled in vision therapy for treatment of convergence insufficiency.

Keywords: acquired hyperopia, benign syndrome, chorioretinal folds, diplopia

Introduction

Choroidal folds have an appearance of alternating light and dark lines that are often found in the posterior pole.¹ They are typically parallel in arrangement and can vary in length and width depending on their time of origin. Choroidal folds are arguably more distinguishable under fluorescein angiography (FA), as FA often reveals an expansion of the folds in area and number beyond what is seen in ophthalmoscopy.²⁻⁴ Histopathologic studies of choroidal folds show involvement of Bruch's membrane, the choriocapillaris, and the overlying retinal pigment epithelium (RPE). Bruch's membrane begins to fold as a result of redundant tissue and congested choroidal vasculature.⁵⁻⁹ The RPE follows and becomes denser in the troughs of the folds as it is bound to the contours of Bruch's membrane. This produces the distinctive striated appearance. Although the RPE is involved, the sensory retina remains largely untouched, which accounts for the general lack of visual symptoms.

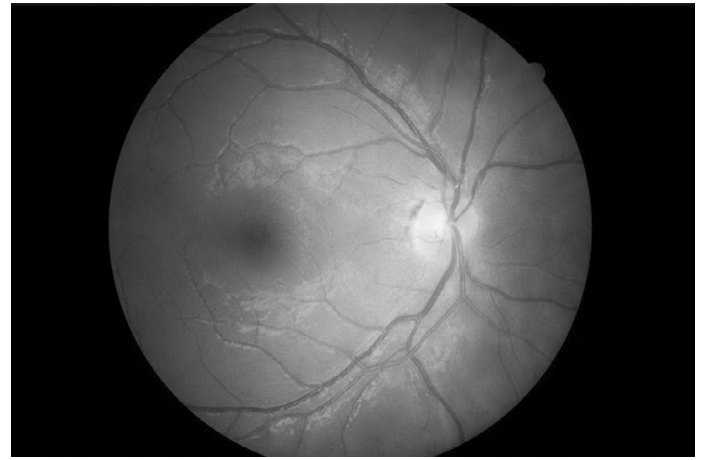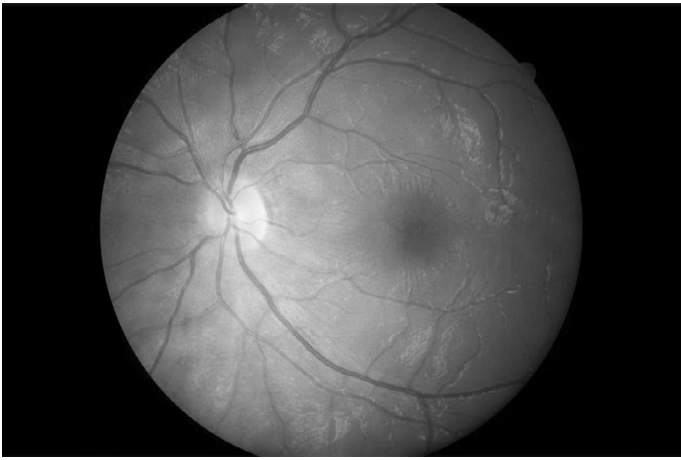
There are a variety of ocular and orbital conditions that have been associated with choroidal folds; however, most cases are idiopathic.¹ Ocular etiologies include: retinal or choroidal detachment, posterior scleritis, scleral buckle, choroidal mass or inflammation, hypotony, chronic papilledema, optic nerve

tumor, choroidal neovascular membrane, central serous chorioretinopathy, microphthalmos, angioid streaks, optic nerve drusen, and trauma to the globe. Orbital etiologies include: orbital mass, orbital inflammation, thyroid eye disease, and pseudotumor cerebri.^{2,10} Acquired hyperopia with choroidal folds correlates to a benign syndrome that has been characterized by:¹

1. A discernible space between the nerve and its sheath
2. Flattening of the posterior pole
3. Distension of the perioptic subarachnoid space
4. Variable enlargement of the optic nerve image
5. Scleral shortening and congestive choroidal thickening

The syndrome is more common in males by a rate of 14:1.⁶

The orientation of choroidal folds may also offer an indication of the underlying etiology. Intra-conal tumors (within the muscle cone) exhibit folds radiating from the optic disc, whereas extra-conal tumors (exterior to the muscle cone) exhibit folds with the convex side facing the optic disc.¹¹ Choroidal folds in hypotony often assume a linear orientation temporal to the optic disc and a quilted pattern nasal to the optic disc.^{4,7}



Figures 1a and 1b. Left eye subtle radiations concentrically from the macula and temporally towards the optic nerve. Right eye normal fundus findings.

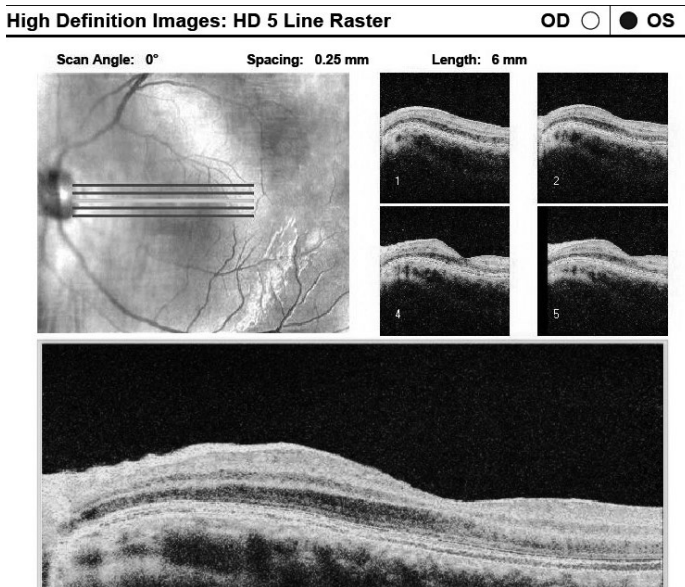


Figure 2. OCT 5 line raster of the macular region of the left eye. Shows folds in the retina temporal to the optic nerve.

Visual acuity is generally unaffected unless the macula is involved,¹² and the etiologies are variable, with some being particularly malicious. Unilateral presentations of choroidal folds are frequently indicative of more severe conditions when contrasted with bilateral presentations.¹³ As such, the proper workup is vital to rule out suspected underlying pathology. This should include brain and orbital imaging to view structural abnormalities and intraorbital or intracranial masses. Other tests to consider including are visual field testing, fluorescein angiography, B-scan ultrasound, and optical coherence tomography (OCT). Interdisciplinary evaluation and co-management may also become necessary depending on the contributing pathology.

Case Presentation

A 26-year-old female presented in 2013 with complaints of intermittent diplopia and frontal headaches that had been increasing over the past year. Being a student, she noticed that she was progressively unable to study for longer than 20

Table 1. Examination Data

	OD	OS
Dist VA uncorrected	20/20	20/40
Best-corrected VA	20/20	20/20
Retinoscopy	+0.25-0.25x180	+2.50-0.50x180
Manifest refraction	PL	+1.50-0.25x010
Refraction from 2011	+0.25 sph	+0.50 sph
Distance cover test	4Δ XP	
Near cover test	8Δ XP	
NPC	more than 20 cm	
BO near vergence	x/12/2	
BI near vergence	24/30/18	
BO distance vergence	x/06/0	
BI distance vergence	x/12/6	
MAF with correction	6 cycles OD, OS	
BAF with correction	failed plus	
MEM with correction	PL OD, OS	
Amp of accommodation	6D OD, 5D OS	
NPC with +1.00 OU	more than 20 cm	
NRA	+2.00	
PRA	-3.25	
BCC	PL	

minutes at a time before symptoms manifested. In 2011, she was diagnosed with convergence insufficiency and was referred for a binocular vision consult to consider vision therapy. However, no follow up was attempted. Her family history was significant for hearing loss secondary to tumor growth. The discovery of hearing loss in 2011 prompted an MRI, which revealed a pineal cyst with no masses or other abnormalities seen. The refractive and binocular data are summarized in Table 1.

Pupils were equal and reactive with no afferent defect. Confrontation fields and extraocular motilities were within normal limits. The anterior segment exam was unremarkable, and intraocular pressures were 14 mmHg taken with the Tonopen. Fundus exam revealed pink and distinct optic nerves and normal vessels. The macula of the right eye was

flat and intact; however, the left eye showed subtle radiations extending temporally from the nerve and concentrically about the macula. Epiretinal membrane and chorioretinal folds were the primary differentials of this particular ophthalmoscopic appearance while also considering the hyperopic shift (Figure 1). Subsequent macular OCT showed slight elevation nasal to the macula with folds seen in the retinal layers (Figures 2 & 3). B-scan ultrasound revealed no masses or gross elevation, but rather flattening of the left posterior pole (Figure 4). A 120-point screening visual field performed on a following visit did not localize any defects (Figure 5).

The binocular data aligns very closely with what is expected of true convergence insufficiency: greater exophoria at near, reduced NPC, poor positive fusional vergence ranges at near, a lead on MEM, reduced NRA, and failure of BAF on plus. To rule out accommodative etiologies for the convergence insufficiency, a trial of plus at near was attempted; however, it did not improve the patient's NPC. She was diagnosed with convergence insufficiency and possible choroidal folds. A neuro-ophthalmology consult was warranted to rule out intraocular or intraorbital masses because of the patient's notable family history and the unilateral nature of the presentation. The evaluation confirmed a diagnosis of choroidal folds and acquired hyperopia. Moreover, the MRI study indicated no masses or abnormalities. The imaging did, however, reveal flattening of the posterior pole of the left eye (Figure 6). A lumbar puncture was recommended to explore the possibility of elevated intracranial pressure. After she had been cleared of pathology, she was enrolled in vision therapy to address her convergence insufficiency.

Discussion

The benign syndrome of choroidal folds and acquired hyperopia has been documented in a number of case studies. Kalina and Mills looked at a study of six adults who developed symptoms of acquired hyperopia who were also found to have choroidal folds.⁶ The onset occurred suddenly both bilaterally and unilaterally. Subjects showed a refractive change between 2 and 6D, with an average of 3.5D. The choroidal folds demonstrated a horizontal pattern temporal to the disc; however, four of the subjects also exhibited fine stellate folds around the foveal region that are descriptive of the pattern seen in our patient. The study noted mildly reduced acuity (one line) in some of the subjects, but overall, the long-term follow-up established the benign course of the syndrome. Visual acuity, refraction, and posterior pole appearance remained stable for up to 23 years.

Some cases of acquired hyperopia with choroidal folds may also present with idiopathic intracranial hypertension or secondary pseudotumor cerebri. Jacobson described a case study of three patients presenting with papilledema and the benign

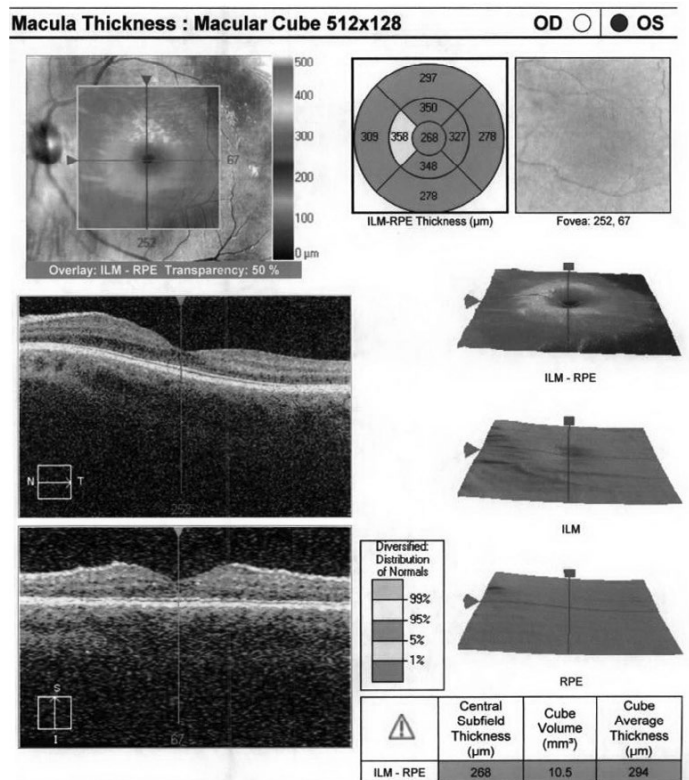


Figure 3. OCT of the macula shows mild thickening nasal to the macula.

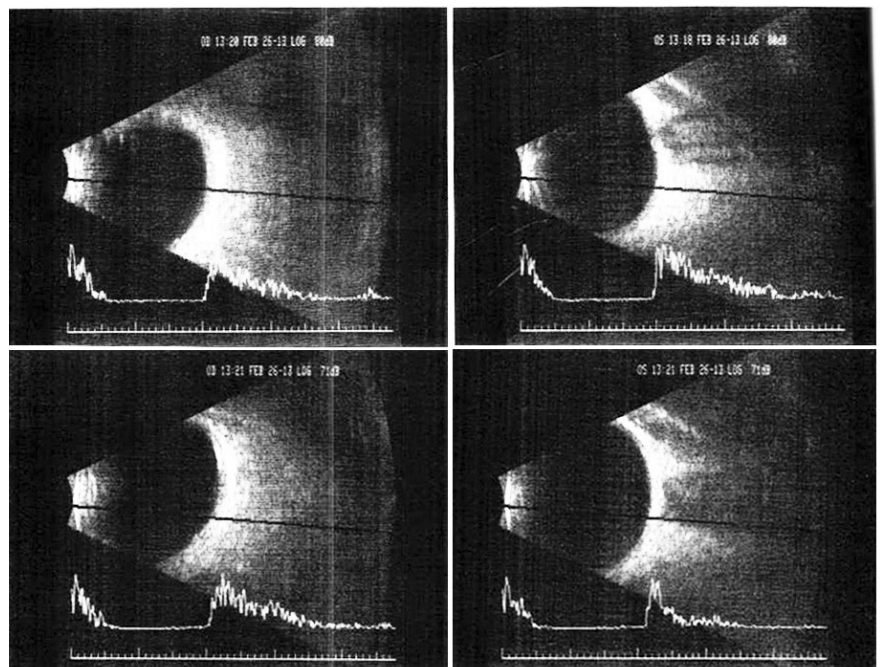


Figure 4. B-scan ultrasound of the left eye. No elevation, gross masses, or abnormalities identified. Some flattening of the posterior pole in the top right scan.

syndrome of acquired hyperopia with choroidal folds verified by imaging characteristics.¹⁴ One patient exhibited unilateral disc edema with bilateral choroidal folds and was diagnosed with idiopathic intracranial hypertension. However, another patient with strictly unilateral findings was found to have only mildly increased intracranial pressure. The last subject showed bilateral choroidal folds for two years preceding bilateral disc edema, also as a result of increased intracranial pressure that

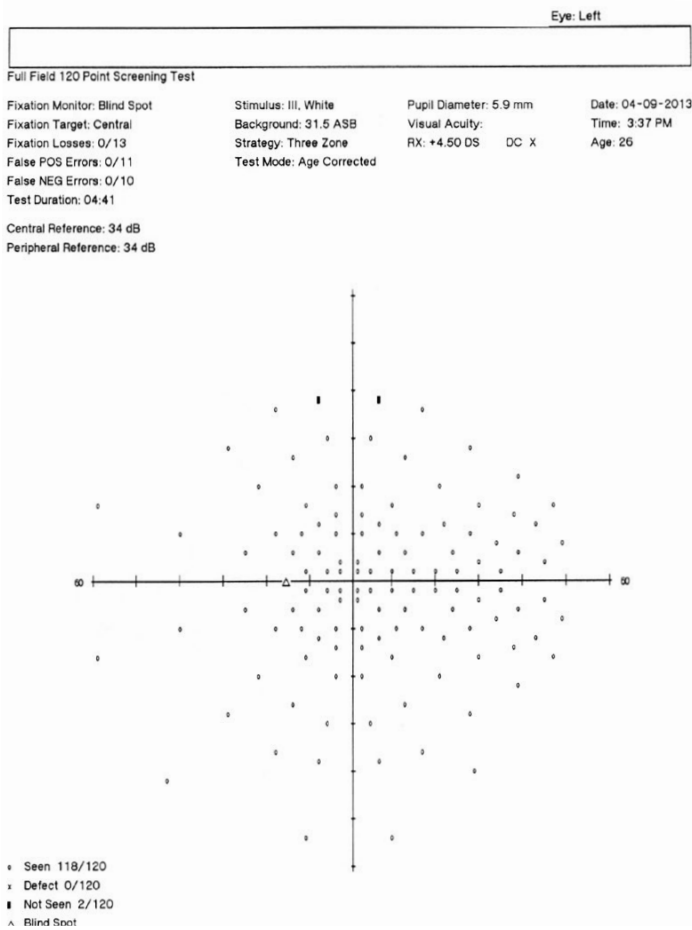


Figure 5. Visual field 120 point screener.

was related to severe chronic obstructive pulmonary disease and pulmonary heart disease. It was suggested that perhaps the syndrome of acquired hyperopia with choroidal folds is representative of an uncommon presentation of idiopathic intracranial hypertension.

A similar study by Griebel and Kosmorsky evaluated 12 patients presenting with choroidal folds.¹⁵ Six presented with disc edema, while six presented with only choroidal folds. Five out of six patients presenting with only choroidal folds had cerebral spinal fluid opening pressures that were indicative of intracranial hypertension. They concluded that choroidal folds can be the presenting sign of increased intracranial pressure and may occur in the absence of disc edema. This may be explained by the timing of the evaluation, as the choroidal folds may be present after resolution of the disc edema. Another explanation offered refers to retrolaminar optic nerve sheath enlargement (a characteristic of the benign syndrome) that permits indentation of the posterior globe without the resultant disc edema. As recommended by both studies, a lumbar puncture in addition to brain and orbital imaging is wise to consider in presentations of choroidal folds.^{14,15}

Pineal cysts are frequently asymptomatic and incidental findings on MRIs. Cysts exist in 23-40% of adults, with a greater proportion occurring in women.¹⁶ Symptoms typically manifest as headaches, although accounts of diplopia, blurred vision, unilateral oculomotor nerve palsy, and Parinaud

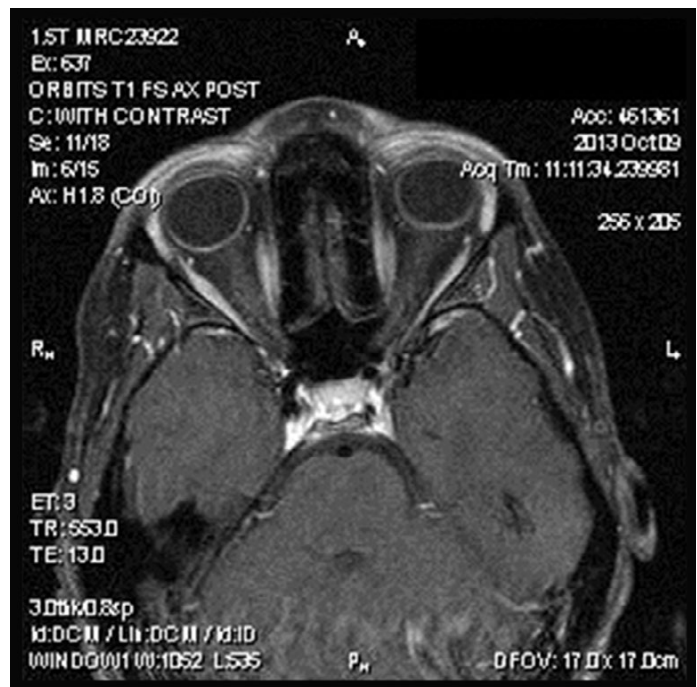


Figure 6. MRI axial cross section reveals no masses or abnormalities. Flattening of the posterior globe in the left eye.

syndrome have been reported as well (symptomatic glial cysts of the pineal gland).¹⁷ In general, symptoms are most common among young women.¹⁶ Our patient fit these characteristics and also presented with the primary complaint of headaches and diplopia. It is more likely, however, that these symptoms are attributed to convergence insufficiency rather than a symptomatic pineal cyst. In numerous studies of symptomatic cysts, diplopia consistently occurs in the company of other serious neurological findings such as gait disturbance, spastic paresis, anorexia, and lethargy.¹⁷

Conclusion

The unique nature of this patient's presentation and history (ipsilateral hearing loss and family history of auditory canal tumors) raised immediate concerns. Choroidal folds have a number of etiologies, ranging from benign causes to malignant masses. They can also be related to or caused by elevated intracranial pressure. The proper workup is therefore critical in determining and managing the underlying causes. Having found no pathology warranting additional attention, the patient was enrolled in vision therapy to address her convergence insufficiency. At the time of this writing, the patient had initiated vision therapy and was steadily progressing until she needed to relocate for graduate school.

References

- Andrew J, James W, Genevieve N. Aetiology and management of choroidal folds. *Clin Exp Optom* 1999;82:169-76.
- von Winning CH. Fluography of choroidal folds. *Doc Ophthalmol* 1972;31:209-49.
- Atta HR, Byrne SF. The findings of standardized echography for choroidal folds. *Arch Ophthalmol* 1988;106:1234-41.

4. Newell FW. Fundus changes in persistent and recurrent choroidal folds. *Brit J Ophthalmol* 1984;68:32-5.
5. Newell FW. Choroidal folds. The seventh Harry Searls Gradle Memorial lecture. *Amer J Ophthalmol* 1973;75:930-42.
6. Kalina RE, Mills RP. Acquired hyperopia with choroidal folds. *Ophthalmology* 1980;87:44-50.
7. Bullock JD, Egbert PR. Experimental choroidal folds. *Amer J Ophthalmol* 1974;78:618-23.
8. Kroll AJ, Norton EW. Regression of choroidal folds. *Trans Amer Acad Ophthalmol Otolaryngol* 1970;74:515-26.
9. Wolter JR. Parallel horizontal choroidal folds secondary to an orbital tumor. *Amer J Ophthalmol* 1974;77:669-73.
10. Franzco D, Franzco M. Acquired hyperopia with choroidal folds. *Clin Experiment Ophthalmol* 2002;30:292-4.
11. Friberg TR, Grove AS Jr. Choroidal folds and refractive errors associated with orbital tumors. An analysis. *Arch Ophthalmol* 1983;101:598-603.
12. Goel N, Kumar V, Raina U, Basudeb G. An unusual pattern of idiopathic choroidal folds. *Oman J Ophthalmol* 2012;5:126-7.
13. Leahey AB, Bruckner AJ, Wyszynski RE, Shaman P. Choroidal folds: A comparison of unilateral and bilateral cases. *Arch Ophthalmol* 1993;111:357-9.
14. Jacobson D. Intracranial hypertension and the syndrome of acquired hyperopia with choroidal folds. *J Neuroophthalmol* 1995;15:178-85.
15. Griebel S, Kosmorsky G. Choroidal folds associated with increased intracranial pressure. *Am J Ophthalmol* 2000;129:513-6.
16. Taraszewska A, Matyja E, Koszewski W, Zaczyński A, et al. Asymptomatic and symptomatic glial cysts of the pineal gland. *Folia Neuropathol* 2008;46:186-95.
17. Fain J, Tomlinson F, Scheithauer B, Parisi J, et al. Symptomatic glial cysts of the pineal gland. *J Neurosurg* 1994;80:454-60.

Correspondence regarding this article should be emailed to Michael Au, OD, at michau@nova.edu. All statements are the author's personal opinions and may not reflect the opinions of the representative organizations, ACBO or OEPE, Optometry & Visual Performance, or any institution or organization with which the author may be affiliated. Permission to use reprints of this article must be obtained from the editor. Copyright 2017 Optometric Extension Program Foundation. Online access is available at www.acbo.org.au, www.oepf.org, and www.ovpjournal.org.

Au M. Benign or malign? A syndrome of acquired hyperopia with choroidal folds. *Optom Vis Perf* 2017;5(1):6-10.

The online version of this article contains digital enhancements.