

Article ▶ Functional Vision Loss: A Case Report and Discussion of Conversion Disorder in the Optometric Setting

Katherine Munsey Welch, OD, Huntington, West Virginia

ABSTRACT

Conversion disorder is a mental disorder that manifests as altered sensory or motor function in the absence of a corresponding medical diagnosis. It is regularly encountered in medical rather than psychiatric settings. Functional vision loss due to conversion disorder should be considered when visual complaints are present in the context of normal ocular health. It is important for optometrists to have an understanding of conversion disorder in order to reach a diagnosis and to initiate appropriate management promptly, while also excluding the possibility of other neurological or ocular disease.

Keywords: Conversion disorder, functional vision loss, nonorganic vision loss, PTSD, visual field

Introduction

Unexplained vision loss presents a unique diagnostic and management challenge in the optometric setting. In some cases, subjective visual complaints without supportive examination findings are more directly associated with the patient's mental health status than with the visual system itself. Conversion disorder is a psychiatric condition in which motor or sensory symptoms, including vision loss, cannot be explained by recognized neurological or medical conditions. These symptoms can cause the patient considerable anguish and distress in several aspects of daily activity. The term "functional" is often used to describe the symptoms of conversion disorder.¹

Functional vision loss, or non-organic vision loss, refers to loss of visual acuity or visual field in the absence of pathologic disease but implies an underlying psychological basis.² The primary concern in making the diagnosis of conversion disorder or functional vision loss is inadvertently overlooking organic disease and denying appropriate treatment.³ As organic and non-organic disease often coexist, positive findings during an examination must be made in order to demonstrate a normal-functioning visual system. Therefore, functional vision loss is a diagnosis of exclusion.⁴

Case Report

A 32-year-old Caucasian female veteran presented to the Eye Clinic on September 17, 2014 complaining of blurry vision and eye pain in the left eye. She reported a sudden onset of symptoms earlier that morning while in the shower, without either improvement or worsening since onset. The patient described the eye pain as dull, radiating backward from the left eye, and rated in severity as 3/10. She also noted increased lacrimation of the left eye at the same time, which had improved since onset. She denied history of ocular injury, recent headaches or migraines, pain on eye movement, photopsia, or amaurosis fugax. She also denied visual symptoms or pain in the right eye.

The patient's last ocular examination was in June 2014. At that visit, she reported monocular vision loss in the left eye that lasted for 5 hours. Onset was one month prior and coincided

with "pressure" behind the left eye that persisted for 4 to 5 days. She described the sensation of pressure as "something pushing on the eyeball." Best-corrected acuities at that examination were 20/30+ OD and 20/30+ OS. Internal and external ocular health was unremarkable, and no ocular etiology was found.

At a previous examination in 2011, the patient reported a history of loss of consciousness and "blacking out of vision" in both eyes while in the military service. Ultrasound imaging of the carotid/vertebral arteries performed in 2011 revealed no stenosis of the right or left internal carotid arteries. Ocular health was unremarkable, and again the etiology of the patient's complaints was not determined.

The patient's medical history was significant for migraines with aura, hypothyroidism, endometriosis, osteopenia, and chronic pain of the wrist, neck, and back. She also had a documented history of depressive and anxiety disorders, as well as bipolar disorder and PTSD. Family history was unremarkable. Chart review revealed a history of sexual trauma during adolescence and a subsequent suicide attempt, as well as military sexual trauma during her Air Force service. She participated in counseling for alcohol abuse while on active duty. Previous psychological testing indicated gross exaggeration of symptoms and functional impairment. The patient was on several medications at the time of examination (Table 1):

Table 1. Medication List

Medication	Dose	Indication
Aripiprazole	20 mg	Mood
Calcium / Vitamin D	250 mg / 125 UNT	Bones / Osteopenia
Bupirone HCL	5 mg	Anxiety
Diclofenac NA	50 mg	Pain
Divalproex	250 mg 24hr (ER)	Migraine Headaches
Divalproex	500 mg 24hr (ER)	Migraine Headaches
Conjugated Estrogens	0.3 mg	Hormone Replacement Therapy
Levothyroxine Na	0.075 mg	Hypothyroidism
Sertraline	100 mg	Depression
Sumatriptan Succinate	50 mg	Migraine Headaches
Topiramate	50 mg	Migraine Headaches
Trazadone	100 mg	Depression

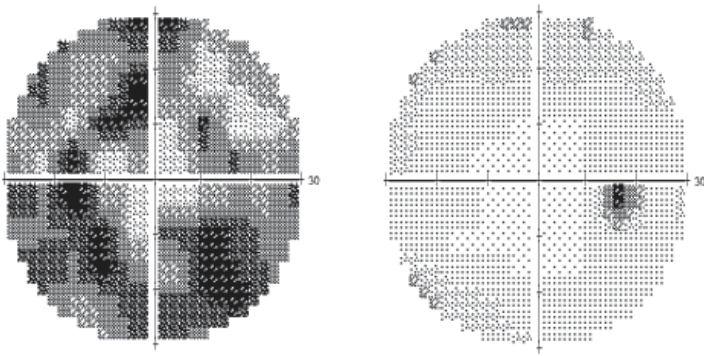


Figure 1. Gray scale plots of 30-2 SITA-Fast Humphrey Visual Field testing OS (left) and OD (right)

Aided distance acuity was 20/20 OD and 20/20-1 OS with minimal refractive error. Pupils were equally round and reactive to light; no relative afferent pupillary defect was noted. Extraocular motilities were full and smooth OU without pain or diplopia. Confrontation visual fields were full to finger count OD, but constriction was noted in all four quadrants OS. Slit lamp examination of the anterior segment was normal except for inferior superficial punctate keratitis (SPK) of the corneal epithelium in both eyes. Intraocular pressures (IOPs) by Goldmann applanation tonometry were 10 mmHg OD, OS. Pupils were dilated with one drop of 1% tropicamide and one drop of 2.5% phenylephrine OU. Dilated assessment of the posterior segment showed remarkably healthy internal structures.

A 30-2 SITA-Fast Humphrey Visual Field was performed with dilated pupils OU (Figure 1). Testing was fairly reliable OD (3/12 fixation losses) and revealed scattered depressed edge points. The mean deviation was -3.07 dB. The visual field was unreliable OS (10/17 fixation losses) but showed extensive inferior greater than superior visual field depression not respecting horizontal or vertical midlines. The mean deviation was -17.87 dB.

Because of the poor test reliability for the left eye, kinetic perimetry was performed. Kinetic testing showed visual field constriction 360° with greater sparing temporally (Figure 2). The visual field extent OS was approximately 90° in the horizontal meridian and 56° in the vertical meridian.

Dry eye was considered to be the etiology of the patient's pain, but no pain reduction was elicited upon instillation of Fluress (fluorescein sodium and benoxinate hydrochloride ophthalmic solution USP 0.25%/0.4%). Because of the unknown etiology of the patient's eye pain and due to the visual field constriction OS, Computerized Tomography (CT) without contrast of the head and orbits was performed on the day of the examination, which was normal.

Follow-up #1

The patient returned as scheduled one week later, reporting a new pain symptom around the temporal area of her left lower eyelid. She stated that it felt like "something [was] trying to come out of it." The pain was sharp, non-

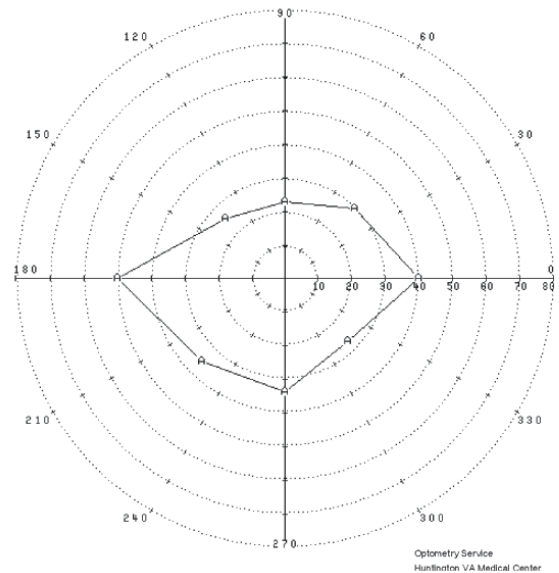


Figure 2. Kinetic perimetry of the left eye




Figure 3. Gray scale plots of Humphrey Visual Field testing OS (left) and OD (right) at follow-up #1.

radiating, and fairly constant. The patient also stated that the dull pain OS had not changed since the initial onset. Her right eye had neither pain nor change in acuity, but she did report an improvement in visual acuity OS.

Corrected visual acuities were 20/20-2 OD and OS. Essentially all findings from the previous examination were stable. Color vision and red cap desaturation were both normal. Gonioscopy was performed to rule out intermittent angle closure as the source of eye pain/pressure; all angles were open to ciliary body without synechiae or recession. Although a repeat 30-2 HVF was scheduled at this follow-up examination, confrontation visual fields were performed at three feet and six feet. The extent of field was roughly twice as great at the doubled distance, with the inferior meridian being the most constricted at six feet.

Automated visual fields were repeated. The right eye had new visual field defects, and the left eye revealed a generalized cloverleaf pattern (Figure 3). Kinetic perimetry was also repeated. It showed field constriction 360°, OS greater than OD (Figure 4). The visual field extent OD was approximately 92° in the horizontal meridian and 59° in the vertical meridian. The visual field extent OS was approximately 67° horizontally and 59° vertically.

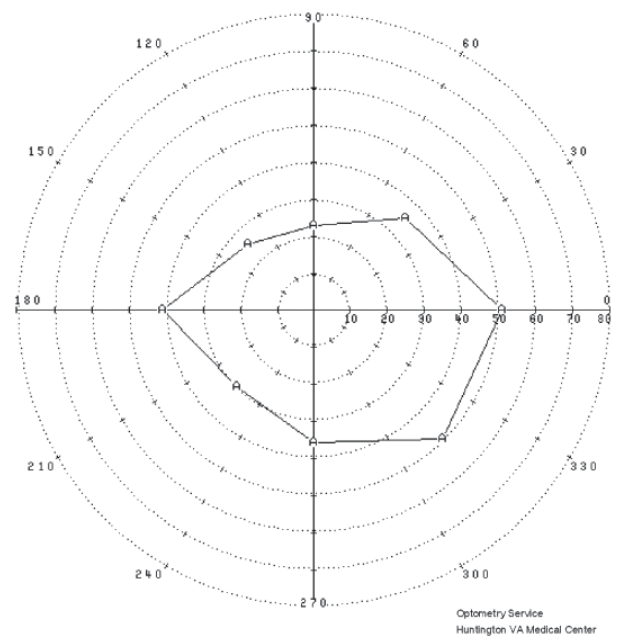
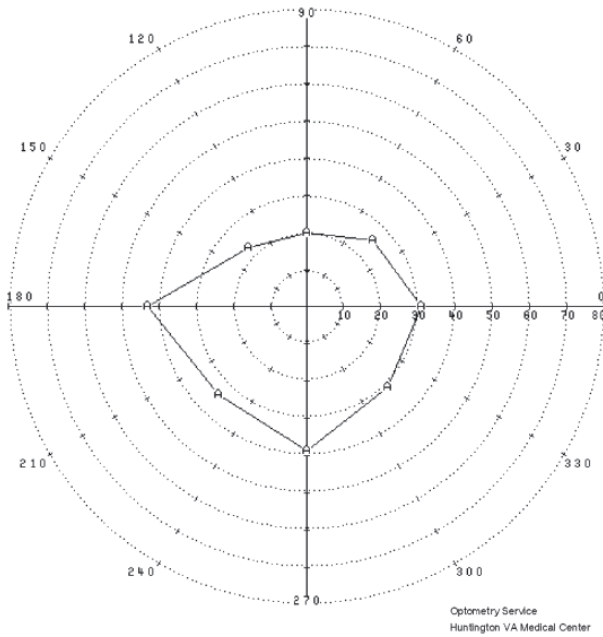


Figure 4. Kinetic perimetry OS (left) and OD (right) at follow-up #1

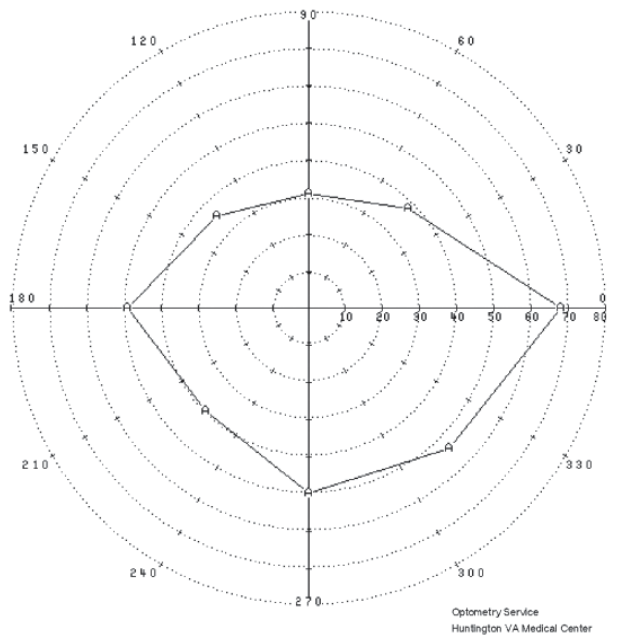
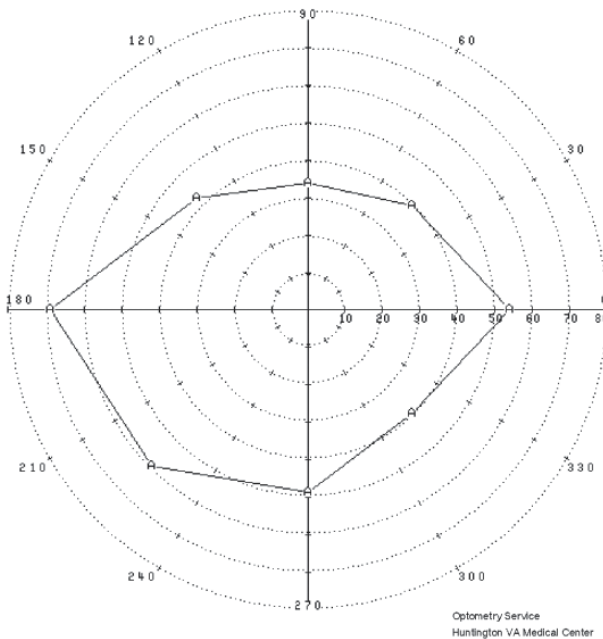


Figure 5. Kinetic perimetry OS (left) and OD (right) at follow-up #2

With the patient’s progressive visual field constriction involving both eyes and unexplained eye pain complaints in the left eye, Magnetic Resonance Imaging (MRI) of the brain with and without contrast was ordered. Her neurologist was notified regarding the visual field constrictions and negative work-up. He agreed with the planned MRI study and would follow up with her in three weeks.

Follow up #2

The patient was scheduled for a three-week follow-up but returned at two weeks due to waking up with her left

eye swollen shut four days prior. She stated that the swelling had gradually resolved since onset. The patient reported that the sensation of “something trying to come out” of her left lower eyelid had not resolved, but the frequency was now intermittent. She stated that her eye pain, blurred vision, and increased photophobia made her call in sick to work three days prior, which was also the day of her MRI. The imaging was negative for any demyelinating pathologies or obvious sources of the patient’s ocular condition.

Aided distance acuities were relatively stable at 20/20-1 OD and 20/20-2 OS. Examination findings were also relatively stable, but anterior segment evaluation was remarkable for

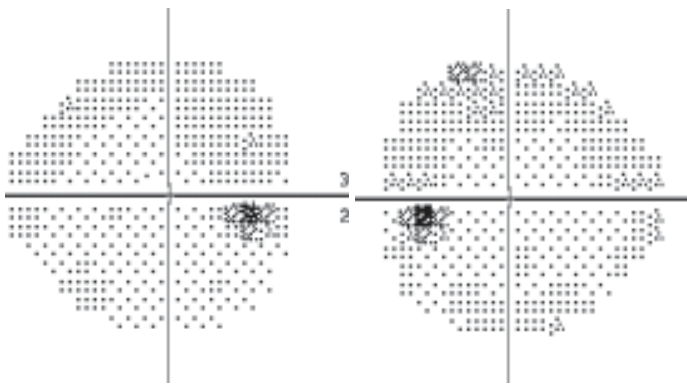


Figure 6. Gray scale plots of Humphrey Visual Field testing OS (left) and OD (right) at follow-up #2

grade 1 papillae of the inferior palpebral conjunctiva OU and continued inferior punctate keratitis OU. Upon questioning, the patient did admit to experiencing itching of the eyes OU, but she denied any other eye irritations.

The kinetic visual fields were improved from the previous visit and were more symmetrical OU (Figure 5). The visual field extent OD was approximately 116° in the horizontal meridian and 81° in the vertical meridian. The visual field extent OS was approximately 123° in the horizontal meridian and 84° in the vertical meridian.

For the patient's ocular allergies, ketotifen was prescribed b.i.d. OU and Refresh Liquigel p.r.n. OU. The leading differential diagnosis at this point for her remaining assessments was conversion disorder. The patient's clinical psychologist agreed that this patient exhibited signs consistent with conversion disorder that could include her unexplained ocular symptoms. The patient had been undergoing regular therapy for significant sleep disturbances, mood alterations, and marital stress related to PTSD. She described willful

avoidance of trauma-related stimuli, including sexual activity. The patient also experienced chronic fatigue, which was impacting her work performance. The psychologist offered to provide continued supportive therapy at their regular sessions with specific attention to conversion disorder. The patient's neurologist was also advised regarding the examination and leading diagnosis.

Follow up #3

The patient returned two months later and stated that she still experienced occasional pain OS, but with significantly less frequency and severity. The patient also reported improved vision OS; she denied any impairment of visual acuity in either eye. Corrected distance visual acuities were 20/20 OD and OS. All examination findings were stable and essentially normal, although with continued mild allergic conjunctivitis. Kinetic perimetry was normal; OD showed 120° horizontal and 96° vertical visual field extent, OS showed 133° horizontal and 98° vertical (Figure 7). A 24-2 SITA-Standard HVF was attempted, as kinetic fields were both full (Figure 6).

The patient was reassured regarding the improvement in visual field testing and the stability of visual acuity OU. She was also reassured that her symptoms would improve with continued ketotifen and Refresh Liquigel. She was advised that no further work-up was deemed necessary at that time in the eye clinic; she was advised to continue follow-up in the neurology and mental health clinics as directed. The patient expressed her thanks; she stated that she felt much better and reported that her symptoms were improving. The patient was instructed to return to the clinic in six months for a comprehensive eye examination.

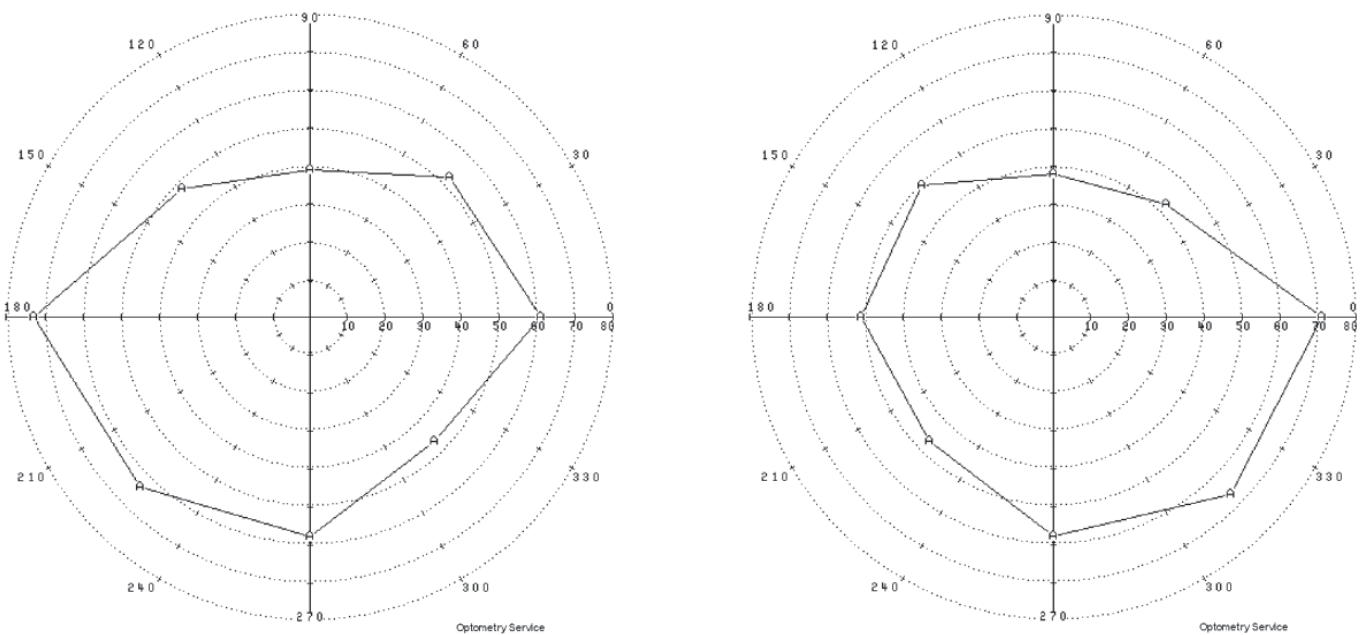


Figure 7. Kinetic perimetry OS (left) and OD (right) at follow-up #3

Discussion

Conversion disorder, also referred to as functional neurological symptom disorder, is broadly defined as the presence of neurological symptoms in the absence of an identifiable neurological disease.⁵ The exact prevalence of conversion disorder is unknown, but the estimated incidence of individual persistent conversion symptoms is 2-5/100,000 per year.¹ It is thought to account for approximately 5% of neurology referrals.^{1,4} Conversion disorder is two to three times more common in females than in males.¹ Although onset can occur at any age, it is less common in children under 10 years of age or in adults older than 35 years.⁵ Environmental risk factors include a history of child abuse and neglect. Stressful life events are also commonly present.¹ A higher incidence in lower socio-economic groups and rural areas has also been documented.⁶

The onset of conversion disorder is mainly attributed to stress or trauma, either psychological or physical in nature. While it is important to evaluate for recent stress or trauma, the diagnosis should not be withheld if no associated trigger is identified.¹ Conversion disorder in the context of military service has historically been associated with violence. A study performed at the Veterans Administration Hospital in Salem, Virginia and the Walter Reed Army Medical Center in Washington, D.C. investigated the role of violence in the development of conversion disorder. The results showed that 70% of patients, both male and female, ascribed their symptoms to a traumatic event or injury. The incidents were sometimes minor and could have occurred months or years previously. A group of patients with anxiety disorders served as one control group, and none attributed his or her illness to an injury. Also, the study found that women were more likely to cite sexual violence as the traumatic event.⁷ These findings, along with the previously mentioned association between a history of child abuse and conversion disorder, are relevant to the patient in this case report, as she experienced sexual trauma during both adolescence and military service.

Functional neuroimaging has been used to study the neural basis of conversion disorder. One study used functional magnetic resonance imaging to evaluate the neurological response of patients with conversion disorder when presented with “fearful,” “happy,” and “neutral” face stimuli.⁶ Patients affected by conversion disorder showed greater right amygdala activity in response to both fearful and happy faces, unlike the control group, which demonstrated heightened amygdala activity during fear stimuli compared to happy stimuli.⁸ The conversion disorder group also showed some evidence of inability to habituate to the emotional stimuli.^{6,8} The amygdala is a key limbic system structure in the formation of memories associated with emotional events, emotional recognition, and threat identification. The results of this study suggest an overall hyper-arousal state in conversion disorder when processing emotional stimuli. Another study also found increased activity

of the amygdala in conversion disorder patients over time when processing fear stimuli, suggesting an impaired amygdala habituation and abnormal emotional regulation.⁸

The fifth edition of the American Psychiatric Association’s Diagnostic and Statistical Manual of Mental Disorders (DSM-5) classifies conversion disorder as a somatic symptom and related disorder. In somatic symptom disorder, physical symptoms that may or may not be associated with another medical condition cause significant disruption in daily life.⁵ The diagnosis of conversion disorder using DSM-5 criteria is contingent upon positive findings that provide evidence of inconsistency between the patient’s symptoms and anatomy, physiology, or accepted medical conditions.¹² The symptoms must cause clinically significant distress or impairment of functioning in social, occupational, or other areas.¹ Compared to the fourth edition, DSM-5 emphasizes the importance of neurological examination and acknowledges that associated conflicts or stressors may not be evident at the time of diagnosis.⁹

Symptoms in conversion disorder may lead to primary and secondary gains for the patient. The “primary gain” is described as the conversion of emotional stimulation into physical symptoms. The external benefits of having symptoms, such as release from responsibilities, are referred to as “secondary gain.”⁵ The concept of secondary gain, however, is not specific to conversion disorder. In making a diagnosis of conversion disorder, it is not required to demonstrate that the symptoms are not intentionally produced because determining the definite absence of feigning is unreliable. However, when evidence of feigning symptoms exists, a diagnosis of factitious disorder or malingering should be considered. Malingering is the intentional reporting of symptoms for personal gain, while individuals with factitious disorder misrepresent signs or symptoms of illness without obvious external reward.^{1,3} Though these conditions should be considered as differential diagnoses, a detailed discussion of distinguishing between conversion disorder, factitious disorder, and malingering is beyond the scope of this paper.

Presentations of conversion disorder can involve any nervous system activity that is under some degree of voluntary control.¹⁰ Common motor symptoms are gait abnormalities, weakness or paralysis, tremor or dystonic movements, or abnormal limb posture. Sensory symptoms typically involve abnormal or reduced skin sensation, hearing, or vision.¹ Other common symptoms include non-epileptic seizures, reduced or absent speech volume, altered articulation, and swallowing difficulties.^{1,10}

Functional, or nonorganic, vision loss due to conversion disorder most often manifests as bilateral, symmetric reduction in visual acuity.¹⁵ Unilateral visual acuity loss is typically more severe than when both eyes are affected.² Diagnosing nonorganic vision loss requires not only the absence of causative findings for the vision loss, but also positive test results that demonstrate the integrity of the patient’s visual

system and that refute the subjective complaints. When examining a patient with suspected nonorganic vision loss, several strategies exist to evaluate monocular and binocular reduction in visual acuity as well as visual field loss.

Assessment of reported monocular acuity loss takes advantage of the ability to test each eye separately under binocular conditions.⁴ One strategy involves fogging the unaffected eye without the patient's knowledge, thereby testing only the affected eye when acuity is tested binocularly.² Similarly, a red-green duochrome chart can be used with a patient wearing red-green glasses. If the patient can read the same line of letters on both sides of the chart, good vision is established in the affected eye.⁴ Stereopsis is another way to evaluate monocular vision loss. High stereoacuity requires good acuity in each eye as well as binocular fusion.² The demand of each stereopsis target is correlated to a minimum visual acuity required in each eye. When monocular vision loss is allegedly severe, the absence of a relative afferent pupillary defect makes an etiology of functional vision loss, refractive error, or media opacity more likely.⁴

One method of evaluating binocular vision loss involves "bottom-up" visual acuity testing.⁴ The patient is first urged to read the smallest line available, usually the 20/10 line, before being shown the 20/15 line and eventually 20/20. Frequently, by the time the 20/20 and 20/25 lines are shown, better vision than originally claimed is established.^{2,4} Another technique that has been proven to be highly sensitive for uncovering functional vision loss is the "distance doubling" acuity test.⁴ This test draws on the principle that if the distance to the acuity chart is doubled, a patient should only be able to read letters twice as large as at the original distance. One study measured the best-corrected visual acuity in 21 patients with functional visual loss and 21 patients with organic vision loss. All of the patients with functional vision loss, but none of the patients with organic vision loss, were able to read the same optotype at double the distance.²

Patients with profound vision loss still maintain physiological reactions to stimuli. The examination of a patient with apparently profound binocular vision loss should begin by observing the patient's ability to navigate to the examination chair, shake hands, and perform other nonvisual tasks.⁴ If acuity is at least light perception, a mirror rotated back and forth in front of the patient should elicit nystagmoid movements as the eyes follow the moving reflections.^{2,4} An optokinetic drum will induce jerk nystagmus if the vision is at least 20/400.⁵ Truly blind patients can easily complete tests of proprioception, such as touching two index fingers together, but a patient with functional blindness will often be unable to perform these tasks.⁴

The most common manifestation of functional visual field loss is constricted visual fields.⁴ When a nonorganic etiology is suspected, confrontation or tangent visual field testing should be performed at two distances. A normal visual field should expand at increased distance, while functionally

constricted visual fields will often "tunnel" or constrict with distance.² Using Goldmann perimetry, functional visual field deficits will typically remain the same size regardless of the stimulus size or brightness used.¹¹ Additionally, a monocular visual field defect that is persistent on binocular testing is assumed to be nonorganic.²

Ancillary testing and imaging are useful in cases where normal visual function cannot be established during the ocular examination. Visual evoked potentials (VEPs) with normal and symmetric amplitude and latency can confirm a functional etiology of monocular vision loss. Abnormal visual evoked responses are less conclusive, as voluntary alteration of evoked potentials is possible. Similarly, a normal and symmetric multifocal electroretinogram (mfERG) response can be used to prove normal visual function, while abnormal testing is inconclusive. Negative neuroimaging studies do not confirm a diagnosis of functional vision loss, but they can be used to rule out a compressive or vascular lesion.⁴

The cornerstone of treatment for functional vision loss is reassurance and follow-up. While placebo treatments such as visual "exercises" or "special glasses" have been suggested, these may serve to undermine the reassurance.⁴ Follow-up appointments are important not only to document improvement, but also to monitor for any co-existent ocular disease.¹¹ Though the evidence base for psychotherapy as treatment for conversion disorder is limited, several small studies have claimed success with psychotherapy, family therapy, and cognitive behavior therapy.¹⁰ Specifically, cognitive behavior therapy strives to reinforce desirable behaviors while eliminating maladaptive ones and is a well-established form of psychotherapy for somatoform disorders.^{5,6}

Given that a short duration of symptoms is a positive prognostic factor in conversion disorder, it is essential to rule out neurological causes and to consider the possibility of psychiatric comorbidity as quickly as possible.⁵ Acute symptoms of conversion disorder often resolve within weeks, but 20-25% of patients may have recurring symptoms within a year associated with a stressful event. Persistence of symptoms is more likely when multiple psychiatric diagnoses are present. Anxiety and depressive disorders are frequently found to co-exist with conversion disorder.¹ Treatment of the associated mental health condition(s) may resolve the primary gain aspect that reinforces the conversion reaction.¹¹

Conclusion

This case of visual field loss due to conversion disorder highlights the profound effect that mental disorders can have on systemic health. In order to make a diagnosis of functional vision loss, a thorough ocular examination must demonstrate the absence of organic disease as well as prove normal visual function. For the patient in this case report, the prognosis is cautiously optimistic, as her visual field defects, eye pain, and vision all improved after several weeks; however, this patient's mental health continues to impair her activities

of daily living on a routine basis. While reassurance and follow-up are effective strategies for managing symptoms, a multidisciplinary approach is essential to identify, to treat, and to continue to monitor any comorbid psychiatric conditions. Conversion disorder and functional vision loss present a unique opportunity for optometrists to play a facilitating role in the mental health care of patients.

References

1. American Psychiatric Association: Diagnostic and Statistical Manual of Mental Disorders, Fifth edition. Arlington, VA: American Psychiatric Association, 2013:309-27.
2. Pula J. Functional vision loss. *Curr Opin Ophthalmol* 2012;23(6):460-5.
3. Barnum R. Problems with diagnosing conversion disorder in response to variable and unusual symptoms. *Adolesc Health Med Ther* 2014;5:67-71.
4. Bruce BB, Newman NJ. Functional visual loss. *Neurol Clin* 2010;28(3):789-802.
5. Qazizada AA, Higgins JC. Sudden vision loss: a case report and overview of conversion disorder. *Consultant* 2014;54(8):606-12.
6. Bonci F. Conversion disorder and visual disturbances in children. *J Behav Optom* 2012;23:134-7.
7. Jones FD, et al., eds. *War Psychiatry*. Washington, DC, the Office of the Surgeon General: TMM Publications, 1989:383-407.
8. Aybek S, Nicholson TR, O'Daly O, Zelaya F, et al. Emotion-motion interactions in conversion disorder: an fMRI study. *PLoS One* 2015;10(4).

9. Stone J, LaFrance WC, Brown R, Spiegel D, et al. Conversion disorder: current problems and potential solutions for DSM-5. *J Psychosom Res* 2011;71:369-76.
10. Alin M, Streeruwitz A, Curtis V. Progress in understanding conversion disorder. *Neuropsychiatr Dis Treat* 2005;1(3):205-9.
11. Feinstein A. Conversion disorder: advances in our understanding. *CMAJ* 2011;183(8):915-20.

Correspondence regarding this article should be emailed to Katherine Munsey Welch, OD, at kcmunsey@gmail.com. All statements are the author's personal opinions and may not reflect the opinions of the representative organizations, ACBO or OEPPF, Optometry & Visual Performance, or any institution or organization with which the author may be affiliated. Permission to use reprints of this article must be obtained from the editor. Copyright 2017 Optometric Extension Program Foundation. Online access is available at www.acbo.org.au, www.oepf.org, and www.ovpjournal.org.

Munsey Welch K. Functional vision loss: A case report and discussion of conversion disorder in the optometric setting. *Optom Vis Perf* 2017;5(3):109-15.

***The online version of this article
contains digital enhancements.***